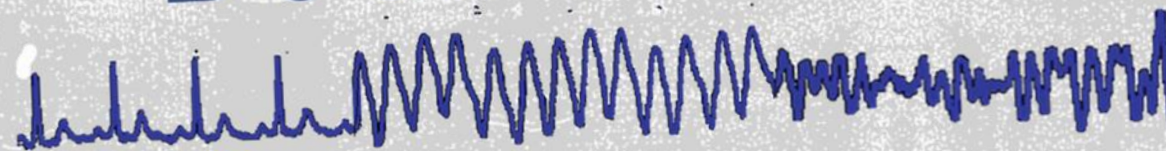
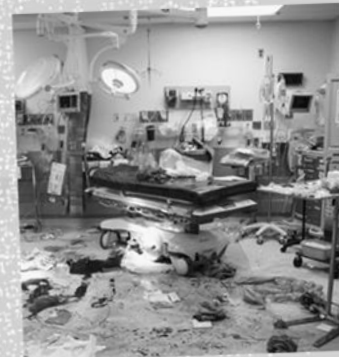




**EMERGENCY MEDICINE**

**BOOT CAMP**





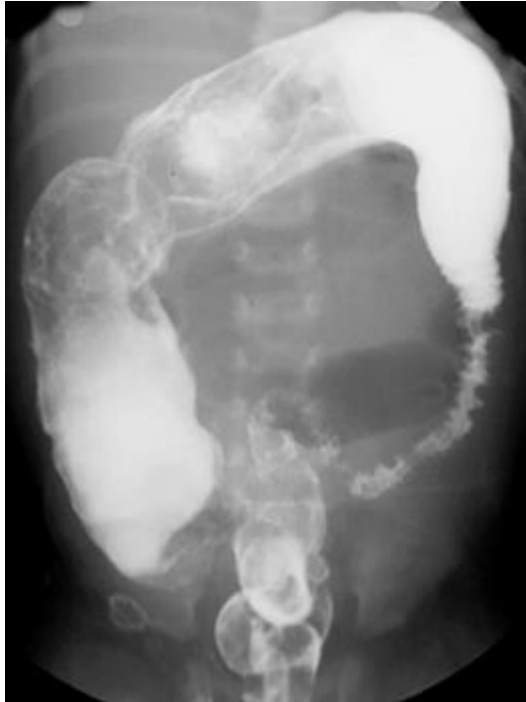# PEDIATRICS



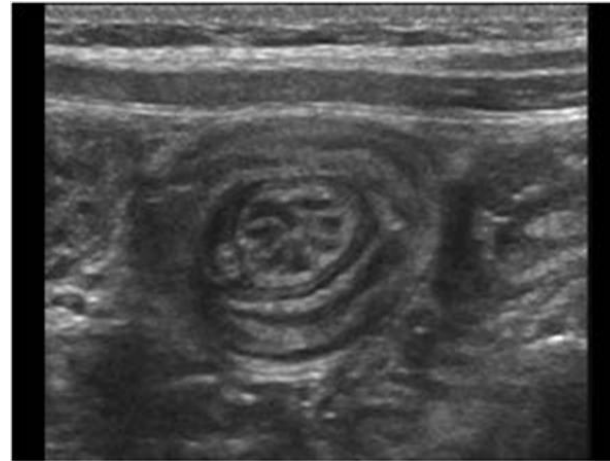**José A. Rubero, MD, FACEP, FAAEM**

**Professor**

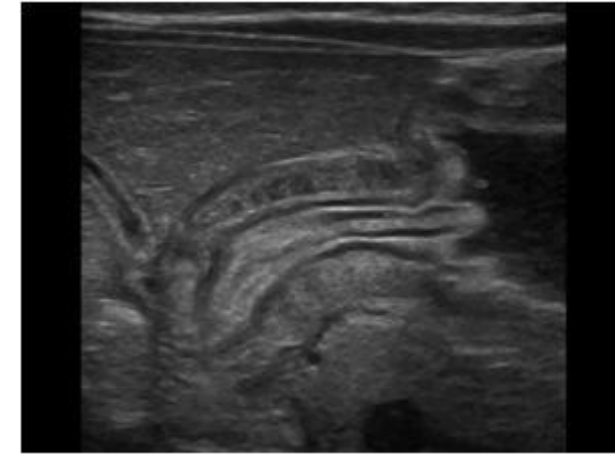
**FOUNDATIONS CHALLENGE**  
**VISUAL DIAGNOSIS**



**1**



**2**

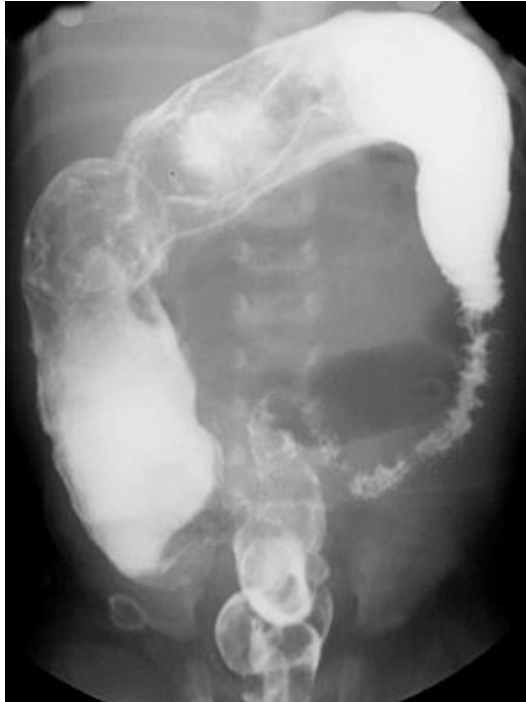

**3**

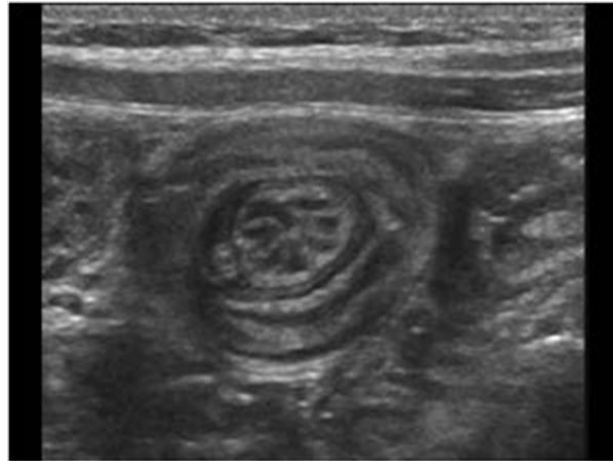**Pediatric Abdominal Pain**

**Diagnosis x 3 ??**

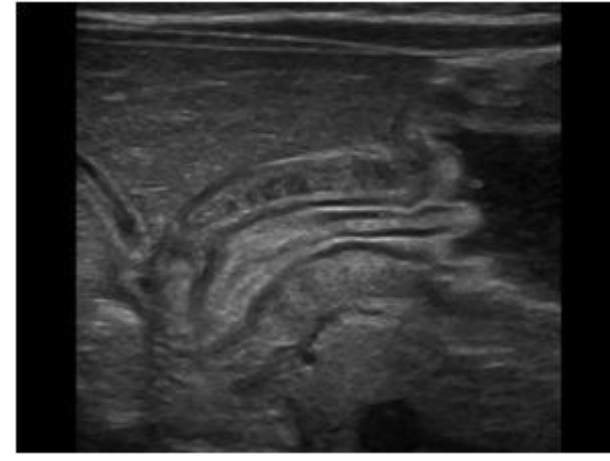
**FOUNDATIONS CHALLENGE**  
**VISUAL DIAGNOSIS**



**Hirschsprung**



**Intussusception**



**Pyloric Stenosis**

**Pediatric Abdominal Pain**

**Diagnosis x 3 ??**



**FOUNDATIONS CHALLENGE**  
**KNOWLEDGE BOMB**

**Pediatric**  
**Abdominal Pain**

▪ **Intussusception**

- Lethargic, currant jelly stools, “sausage-shaped mass”
- XR with obstruction, US with mass (target sign)
- Treat with barium or air enema

▪ **Pyloric Stenosis**

- Non-bilious projectile vomiting in first 2 weeks of life
- Olive-shaped mass, Dx with US (donut or bull’s eye),
- Hypochloremic metabolic alkalosis
- Tx: IVF and surgery

▪ **Hirschsprung Disease**

- No myenteric neural ganglia in distal colon, no passage of stool at 48hr, obstruction and vomiting, risks Toxic Megacolon
- XR: dilated bowel + transition point, with minimal stool in vault
- Tx: surgery



# JAUNDICE

- Occurs in 60-70% of term infants and most premature infants
- Severe jaundice and kernicterus can occur in full-term healthy infants with no apparent hemolysis or any cause other than breastfeeding
- Increased risks of kernicterus with G6PD



# JAUNDICE

- Clinical manifestations:
  - Weight loss
  - Decreased urine output
  - Encephalopathy
    - Early
      - Lethargy, hypotonia, poor feeding
    - Intermediate
      - Stupor, irritability, hypertonia, fever, high pitched cry
    - Late
      - No feeding, apnea, fever, deep stupor to coma, seizures, death



# JAUNDICE

- Major risks:
  - Predischarge total serum bilirubin in high-risk zone
  - Jaundice in first 24 hours
  - Gestational age 35-36 weeks
  - Previous sibling requiring phototherapy
  - ABO incompatibility with positive Coombs or other hemolytic disease
  - Cephalohematoma or significant bruising
  - Adequacy of breastfeeding
  - East Asian race





# JAUNDICE

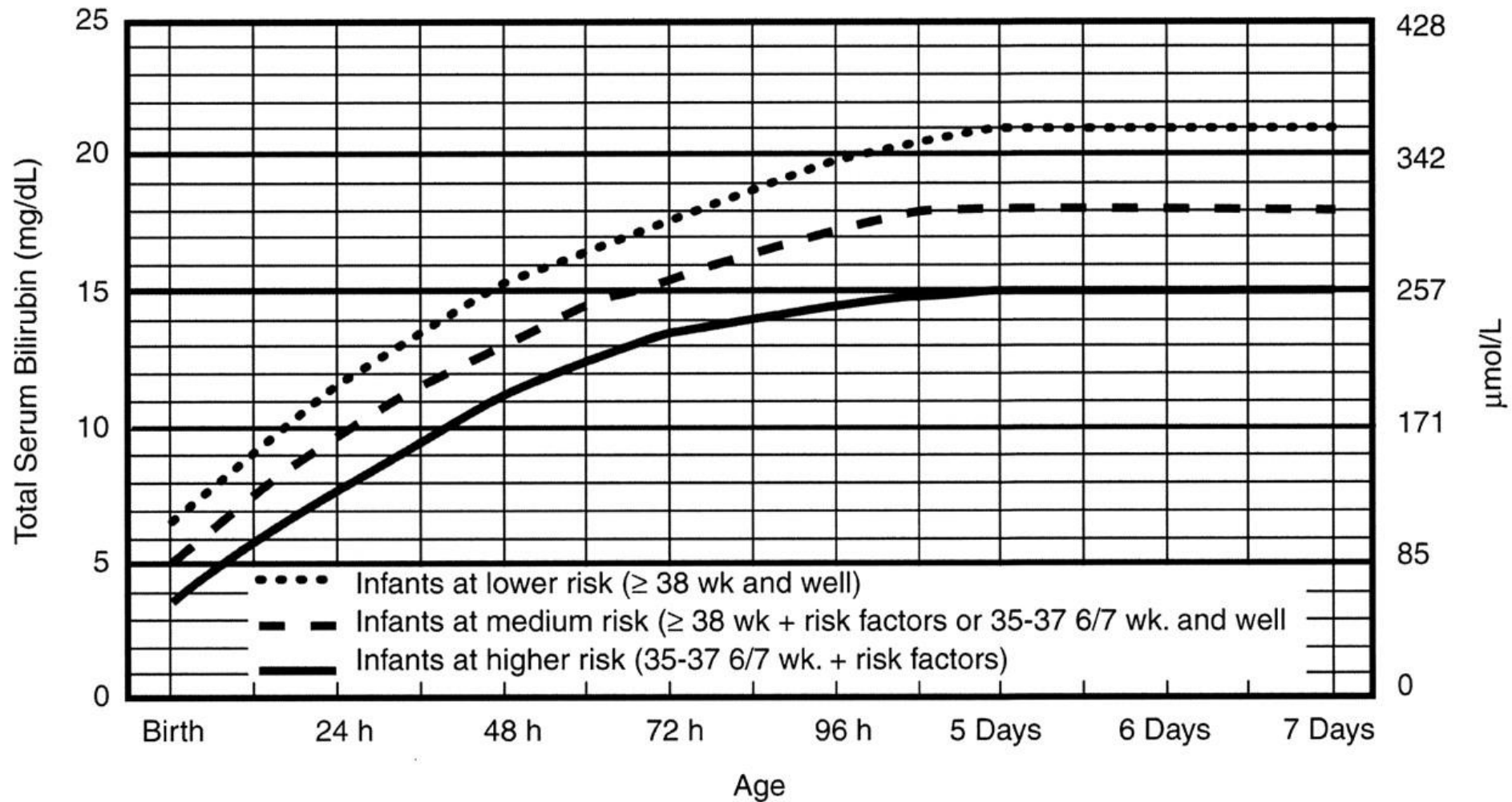
- Management
  - Consider septic work up if jaundice started 2-3 days post delivery
  - If total bilirubin is  $>428$  mol/L, immediate admission to NICU for phototherapy
  - IV gamma globulin for isoimmune disease if TSB level rising despite phototherapy
  - Immediate exchange if encephalopathy and TSB  $> 85$  micromol/L above curve



# JAUNDICE

- Physiologic
  - 2-4 days/old
- 2ry to breast feeding
  - Occurs after 7 days/old
- Septic
  - Poor feeding, respiratory distress, abdominal distention
  - Less than 2 days/old
- Congenital infection, ABO/Rh incompatibility
  - Less than 2 days/old





- Use total bilirubin. Do not subtract direct reacting or conjugated bilirubin.
- Risk factors = isoimmune hemolytic disease, G6PD deficiency, asphyxia, significant lethargy, temperature instability, sepsis, acidosis, or albumin  $< 3.0\text{g/dL}$  (if measured)
- For well infants 35-37 6/7 wk can adjust TSB levels for intervention around the medium risk line. It is an option to intervene at lower TSB levels for infants closer to 35 wks and at higher TSB levels for those closer to 37 6/7 wk.
- It is an option to provide conventional phototherapy in hospital or at home at TSB levels 2-3 mg/dL (35-50mmol/L) below those shown but home phototherapy should not be used in any infant with risk factors.

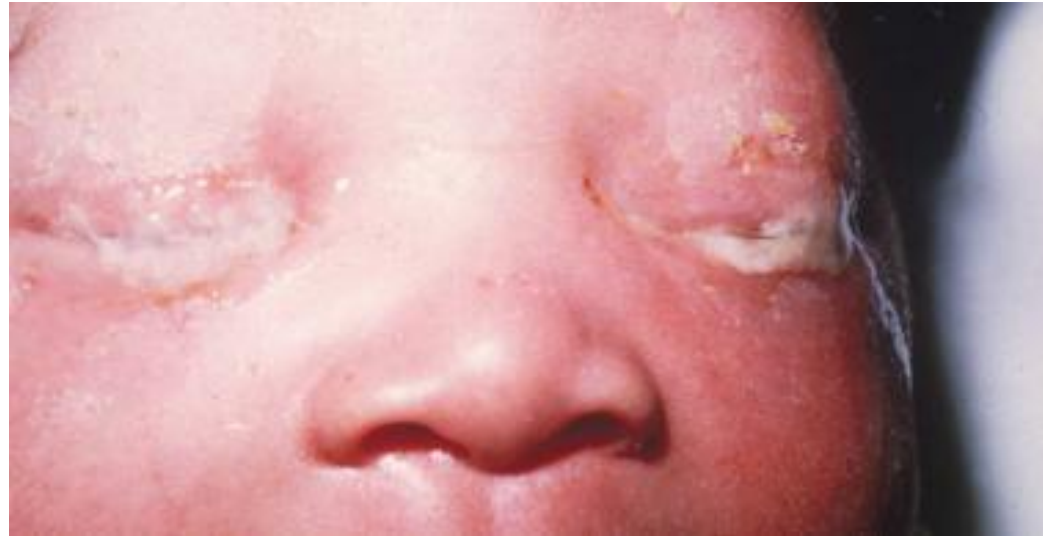

# VOMITING

Nonbilious vomiting	Bilious vomiting
<p>GER</p> <p>Infection: pneumonia, UTI, meningitis, AGE</p> <p>Metabolic</p> <p>Uremia</p> <p>Increased ICP</p> <p>Surgical: pyloric stenosis, proximal duodenal atresia, esophageal atresia ± TEF</p>	<p>Malrotation</p> <p>Intestinal atresia</p> <p>Hirschsprung's disease</p> <p>Meconium ileus</p> <p>Meconium plug syndrome</p> <p>NEC</p>



**FOUNDATIONS CHALLENGE**  
**VISUAL DIAGNOSIS**

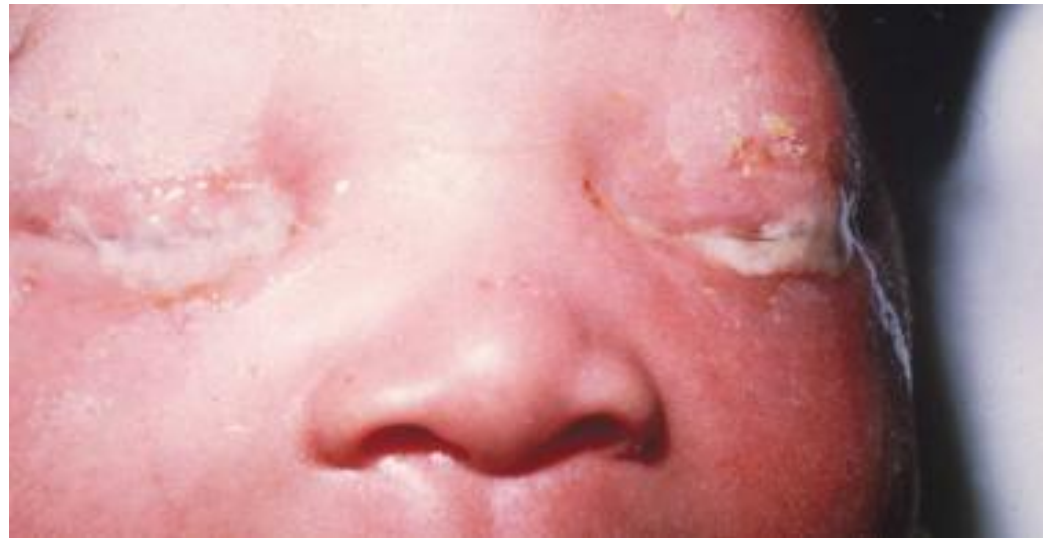

**3 Day Old,  
No Prenatal Care**

**What is the cause?**



**FOUNDATIONS CHALLENGE**  
**VISUAL DIAGNOSIS**



**3 Day Old,  
No Prenatal Care**

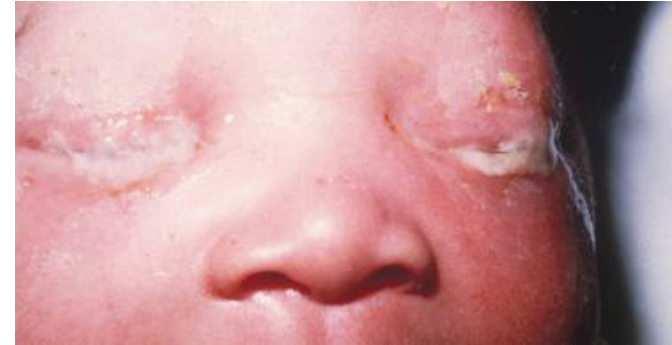***Neisseria gonorrhoeae***



## FOUNDATIONS CHALLENGE KNOWLEDGE BOMB

- **Chemical Conjunctivitis**
  - Mild ssx starting **Day 1**
  - 2/2 Silver Nitrate drops
  - Nothing to do
- **Neisseria gonorrhoeae**
  - Presents **Days 2-7**
  - Severe bilateral purulent d/c, high risk of corneal ulceration/blindness
  - Topical erythromycin or IV cefotaxime or PCN G
- **Chlamydia trachomatis**
  - Presents **Days 5-14**
  - Milder bilateral purulent d/c, risk of pneumonia
  - Oral erythromycin

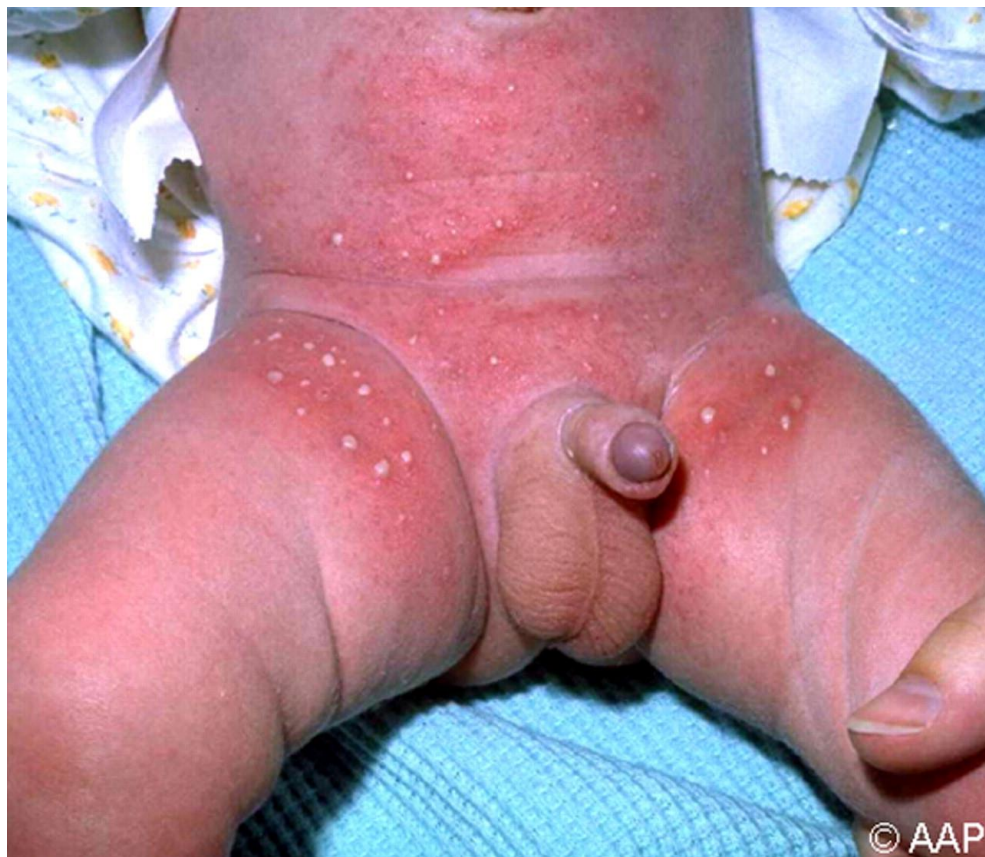## Neonatal Conjunctivitis



**\*\* If systemic illness or rash, consider HSV**

**\*\* Chlamydia is overall the most common cause in neonates.**



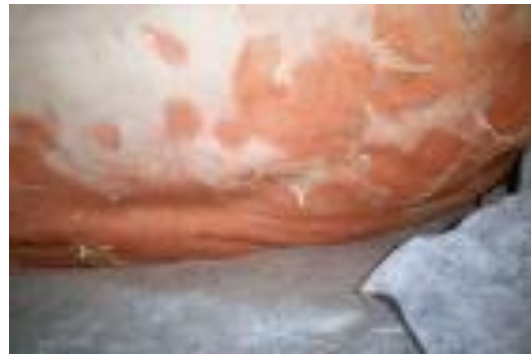
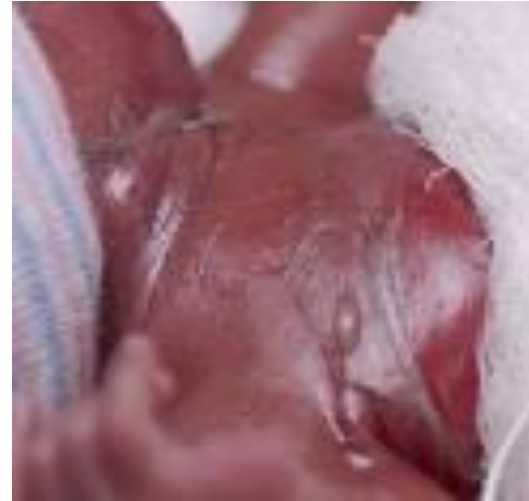
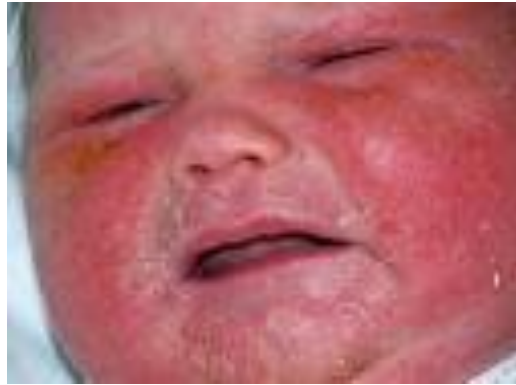

# ***STAPHYLOCOCCAL* PYODERMA**

- Due to *S. aureus* colonization in first weeks of life
- Vesicles, pustules, and bullae arising on normal or slightly erythematous skin
- Common sites: periumbilical region, neck folds, axillae, and diaper area
- Treatment: topical antibiotic, may require cloxacillin or cephalosporin

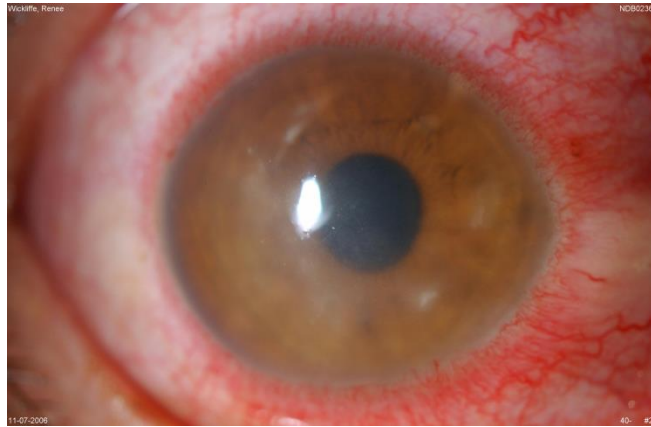
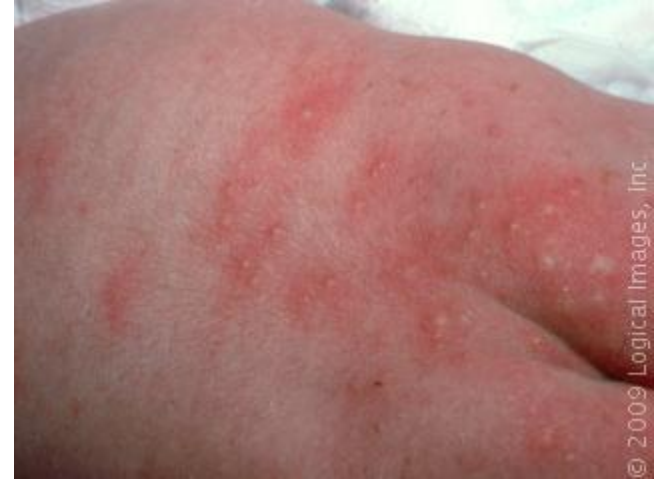
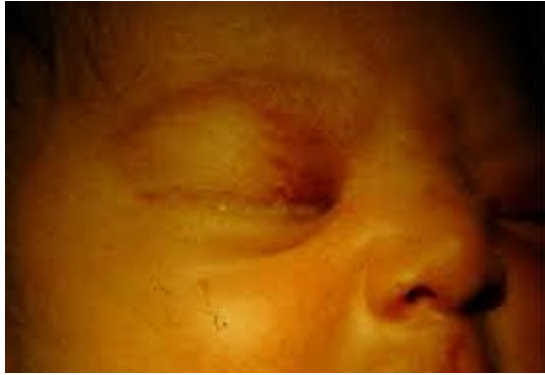


# SSSS (STAPH. SCALDED SKIN SYNDROME)

- Due to endotoxin from certain *S. aureus* strain
- Onset between 3-7 days of fever, irritability, cutaneous tenderness, and erythema
- Nikolsky sign
- Treatment: IV cloxacillin





# HERPES NEONATORUM

- HSV 1 OR 2; 80% due to 2 (poor prognosis)
- Transmission: delivery 85%, in uterus 5%, postnatally 10%
- Higher risk if + in third trimester
- 60-80% of infected infants born to mothers with no history of genital herpes



# HERPES NEONATORUM

- **Clinical manifestations**

- **SEM**

- Presents at day 10-11
    - Discrete vesicles and keratoconjunctivitis
    - Risks of neuro involvement 40% if no meds

- **CNS**

- May present with seizures (50%), lethargy, irritability, tremors, poor feeding, temperature instability, bulging fontanelle, and pyramidal tract signs
    - CSF positive in 25-40%; generally, may have high protein and pleocytosis (mononuclear cells)
    - 40% without vesicles
    - High mortality/morbidity

- **Disseminated**

- Presents at day 9-11 \multiple organ involvement and signs: seizures, lethargy, irritability, respiratory distress, poor feeding, jaundice, bleeding diatheses, shock, and often vesicular rash
    - 22% of the HSV infected neonates
    - 70% survival if treatment; 15% with neuro deficits

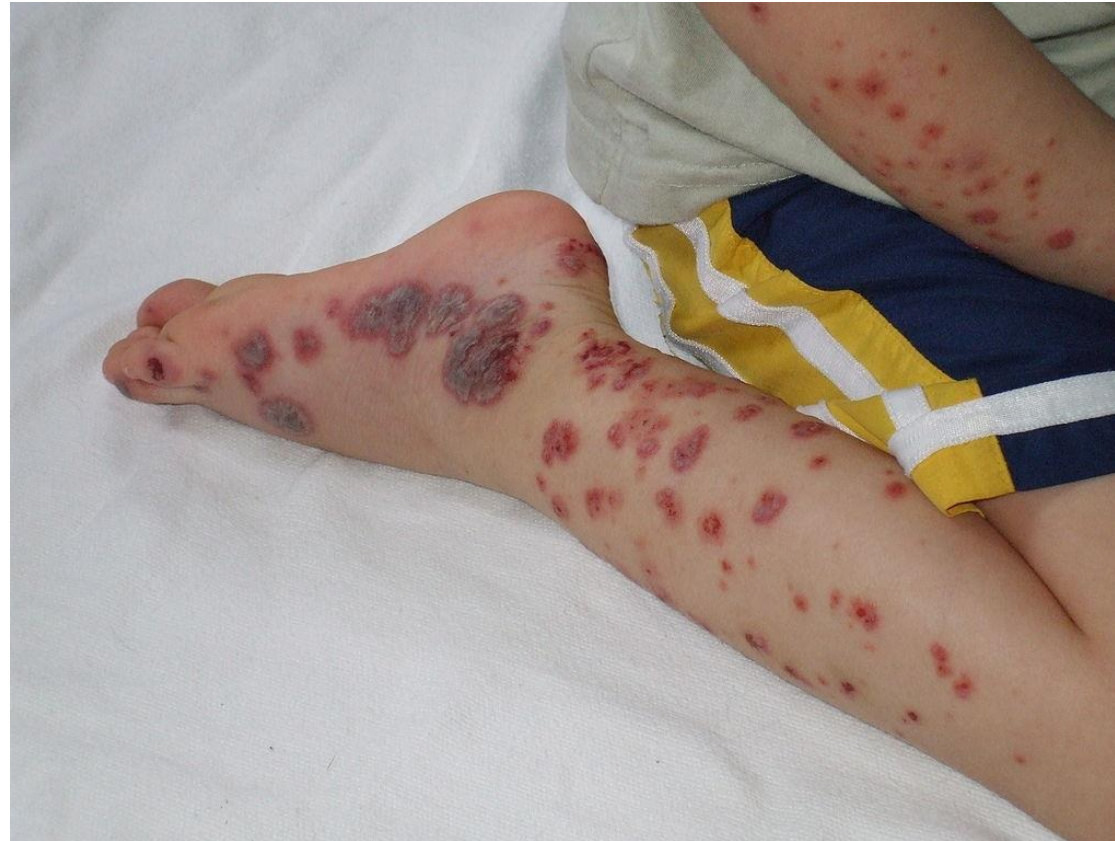

# HERPES NEONATORUM

- Treatment
  - Acyclovir



**FOUNDATIONS CHALLENGE**  
**VISUAL DIAGNOSIS**



6 yo M w/rash

**Diagnosis???**





**FOUNDATIONS CHALLENGE**  
**VISUAL DIAGNOSIS**



**6 yo M w/rash**

**Henocho-Schonlein Purpura**



## **FOUNDATIONS CHALLENGE KNOWLEDGE BOMB**

## **Henoch-Schonlein Purpura**

### **Classic Triad:**

- Abdominal pain
- Arthritis
- Rash "palpable purpura"

### **Potential Complications:**

- Hematuria → Nephritis
- Intussusception
- Subcutaneous edema
- Recurrence

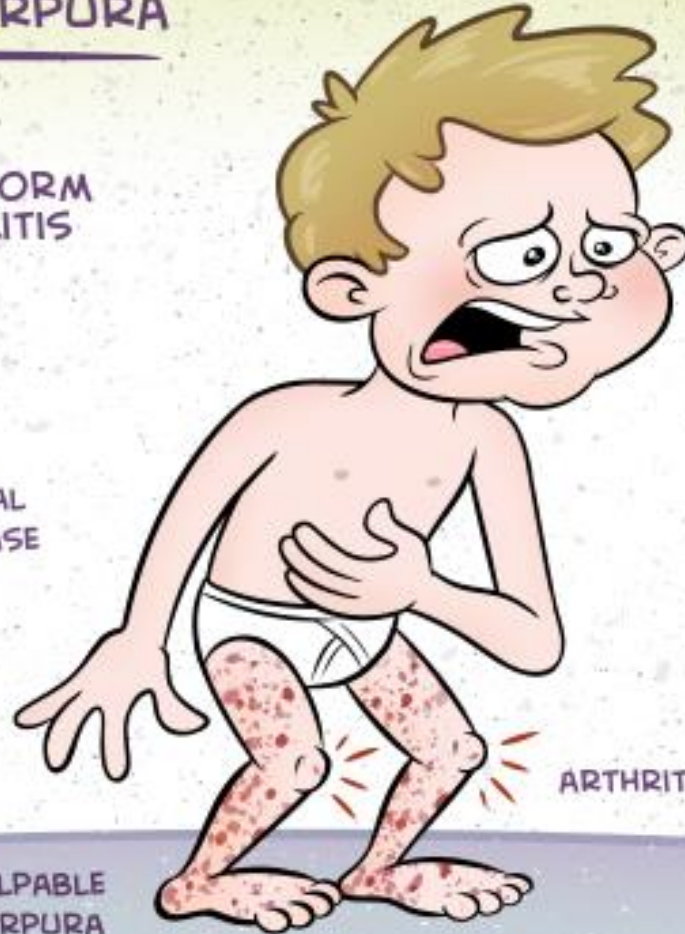

# HENOCH-SCHÖNLEIN PURPURA

THE MOST COMMON FORM  
OF SYSTEMIC VASCULITIS  
IN CHILDREN



RENAL  
DISEASE

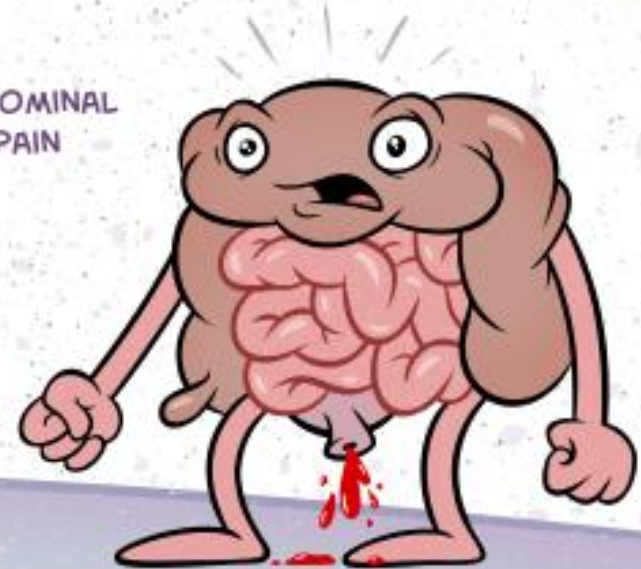


PALPABLE  
PURPURA

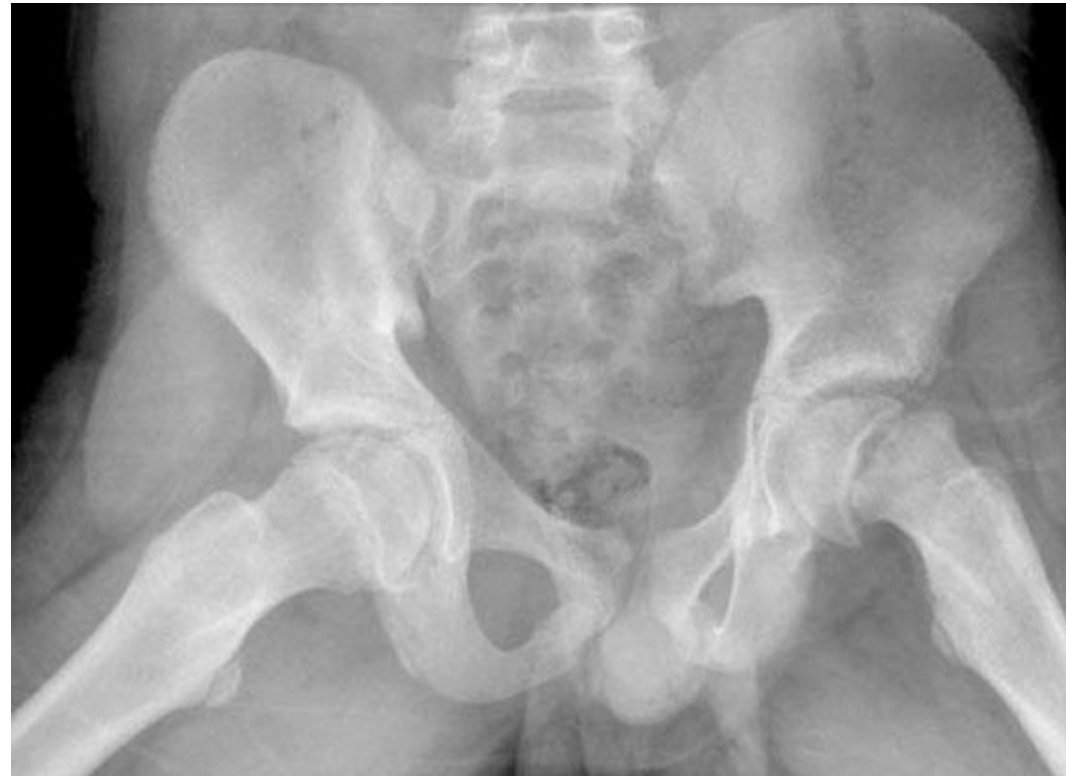ARTHRITIS

BIOPSY OF AFFECTED  
ORGAN DEMONSTRATES  
IgA DEPOSITION

ABDOMINAL  
PAIN



**FOUNDATIONS CHALLENGE**  
**VISUAL DIAGNOSIS**

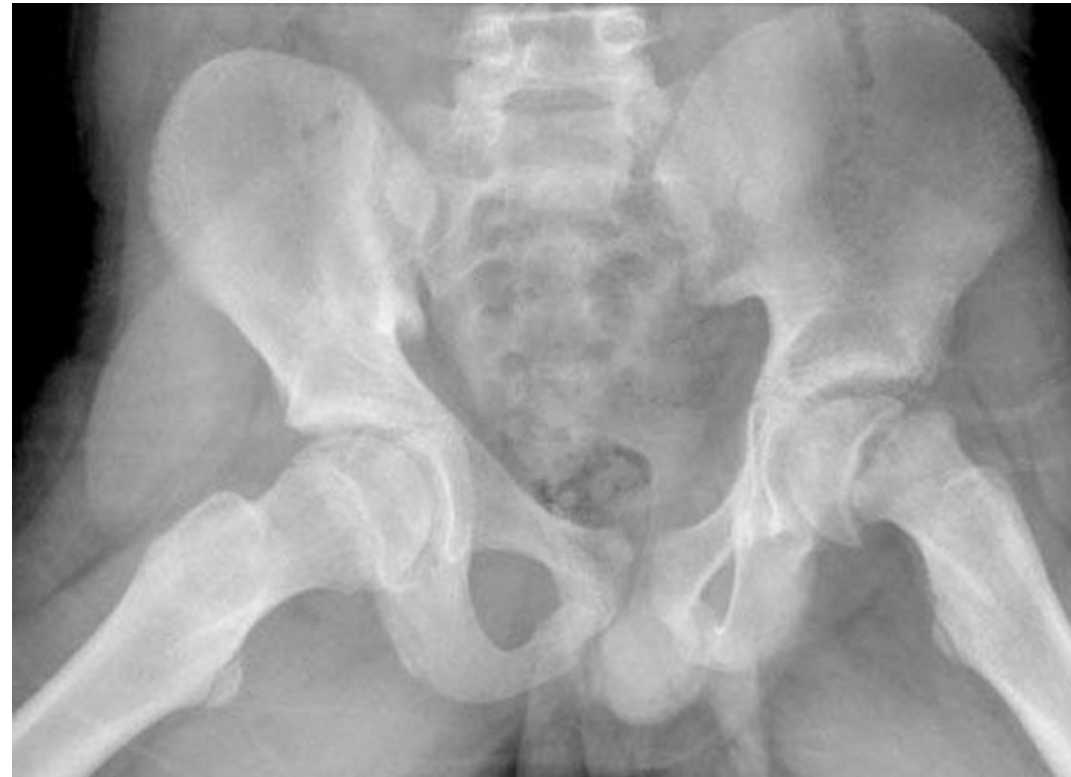

**13yo M w/ Knee Pain**

**Diagnosis & Treatment??**



**FOUNDATIONS CHALLENGE**  
**VISUAL DIAGNOSIS**



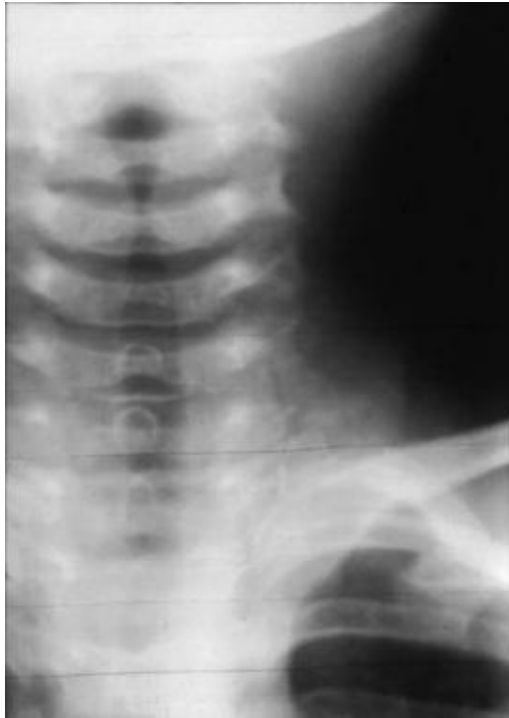13yo M w/ Knee Pain

**SCFE**  
**Requires surgery**

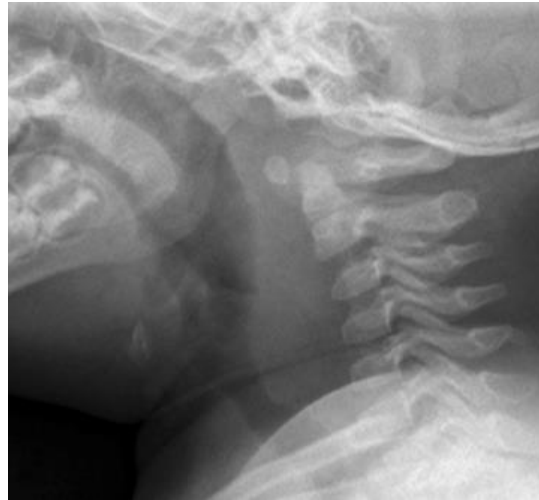

# FOUNDATIONS CHALLENGE

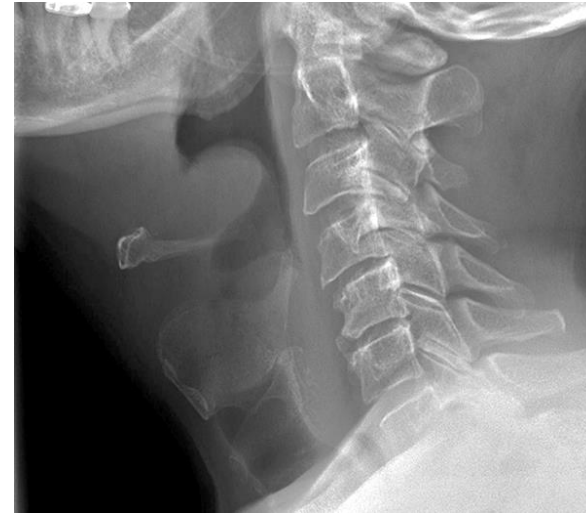## VISUAL DIAGNOSIS



1



2



3

Pediatric Respiratory Distress

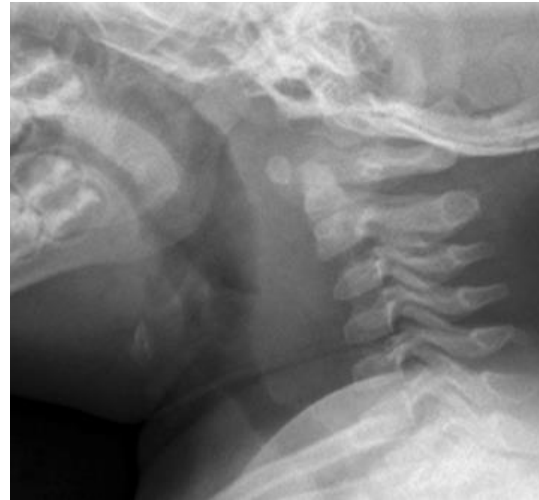Diagnosis x 3 ??



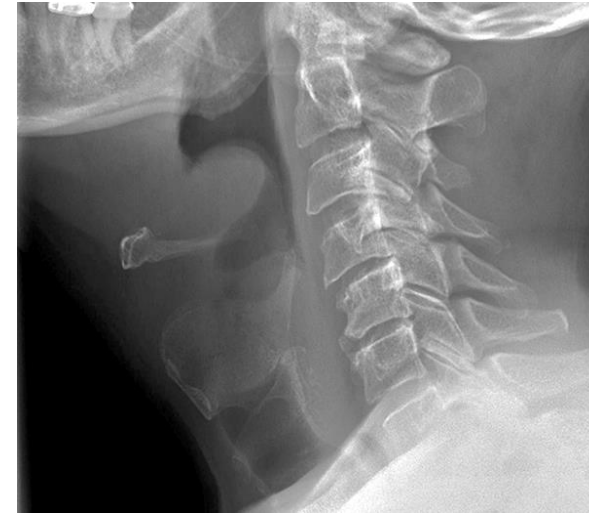**FOUNDATIONS CHALLENGE**  
**VISUAL DIAGNOSIS**



**Croup**



**Retropharyngeal  
Abscess**



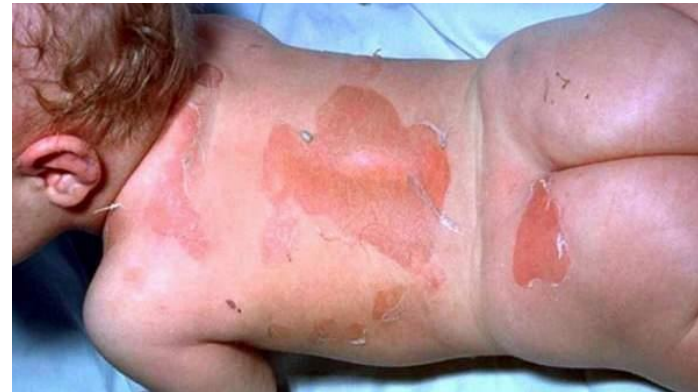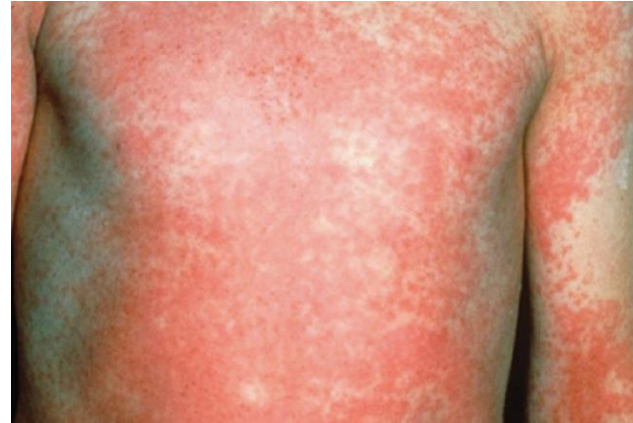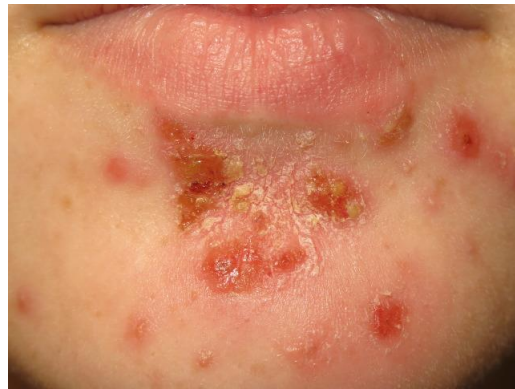**Epiglottitis**

**Pediatric Respiratory Distress**



# FOUNDATIONS CHALLENGE

## VISUAL DIAGNOSIS



Pediatric Staph &  
Strep Skin Infections

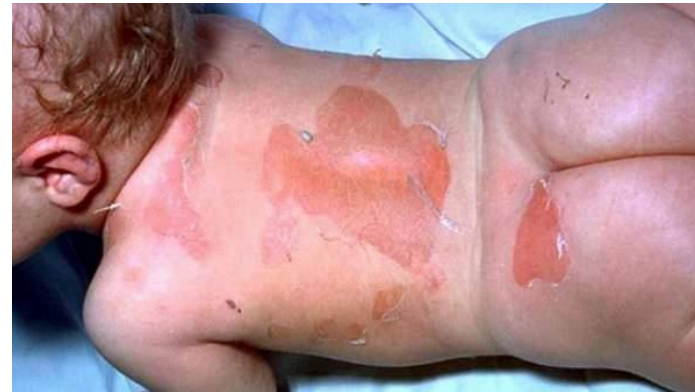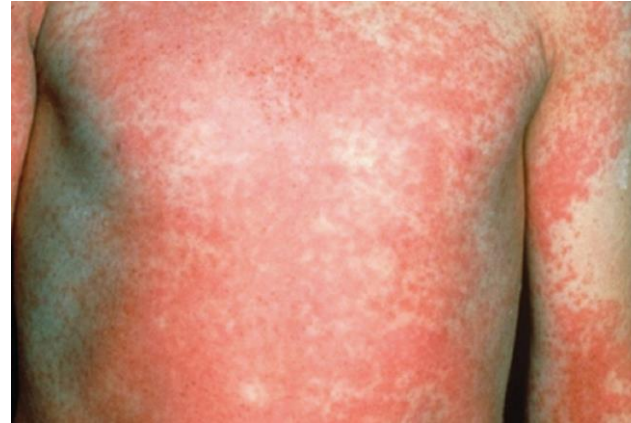Diagnosis x 3 ??





# FOUNDATIONS CHALLENGE

## VISUAL DIAGNOSIS



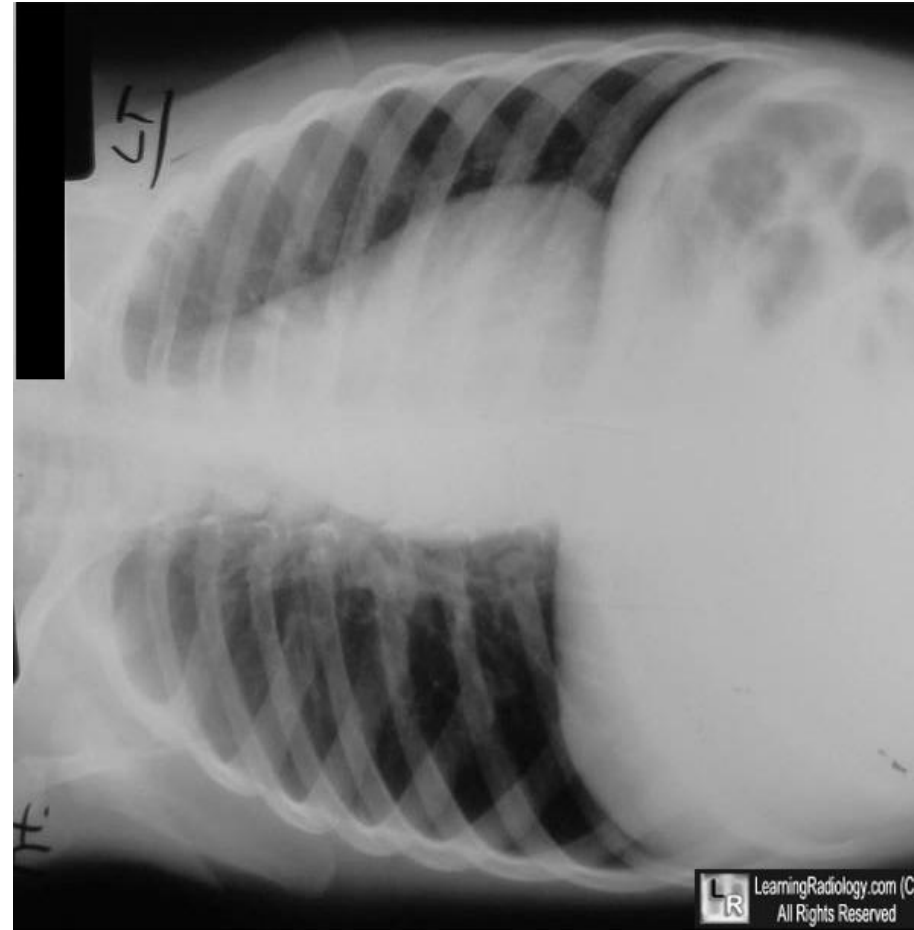
**1) Impetigo**

**2) Scarlet Fever**

**3) Staph Scalded Skin**



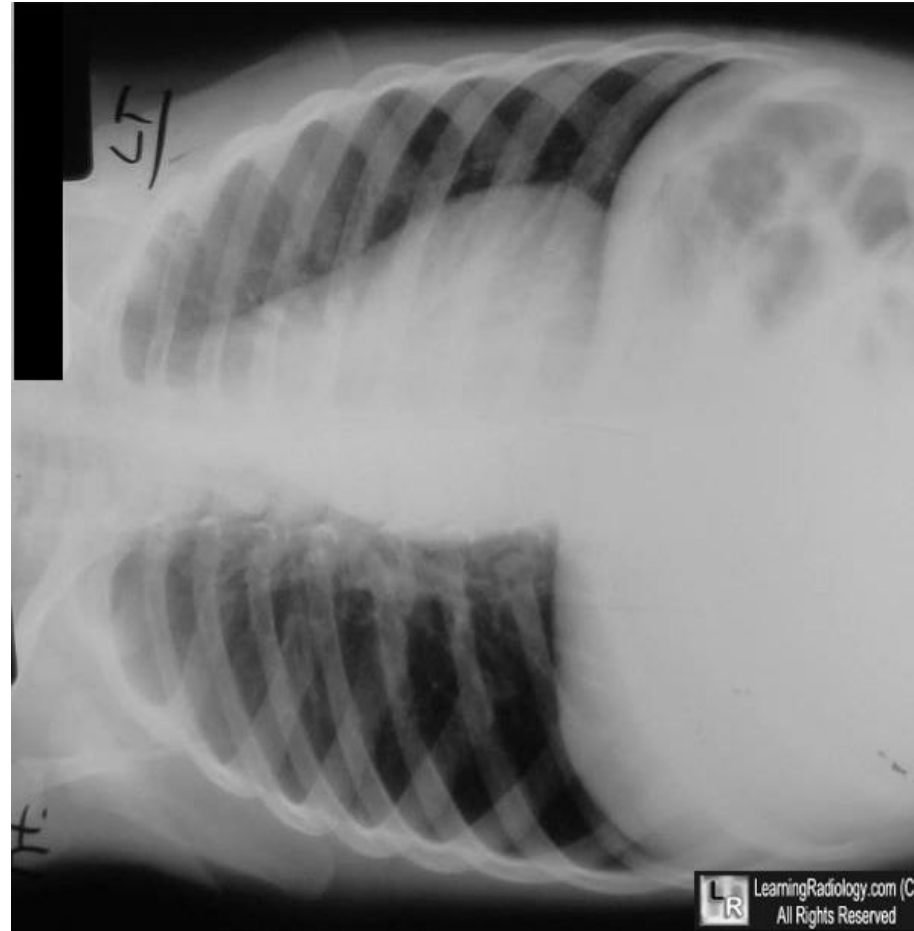
**FOUNDATIONS CHALLENGE**  
**VISUAL DIAGNOSIS**



**Aspirated Foreign Body**

**Right or Left???**

**FOUNDATIONS CHALLENGE**  
**VISUAL DIAGNOSIS**

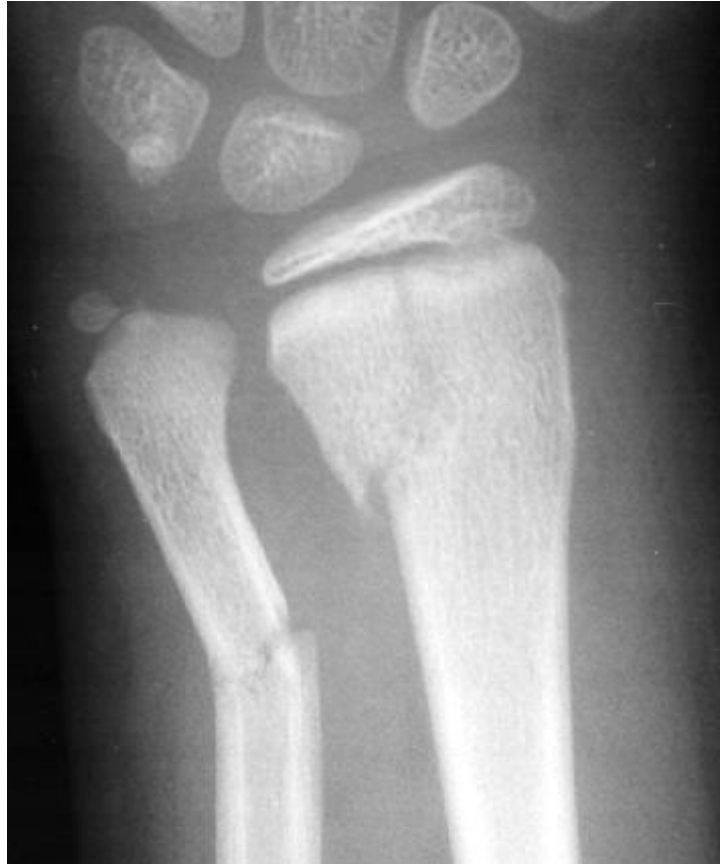

**Aspirated Foreign Body**

**Right**



**FOUNDATIONS CHALLENGE**  
**VISUAL DIAGNOSIS**



**Pediatric Fractures:  
Salter-Harris Classification**

**Distal Radius:  
What Type?**



**FOUNDATIONS CHALLENGE**  
**VISUAL DIAGNOSIS**



**Pediatric Fractures:**  
**Salter-Harris Classification**

**Distal Radius:**  
**Type II**



# FOUNDATIONS CHALLENGE KNOWLEDGE BOMB

# Salter-Harris Classification

**SALTER** describes the relationship to the epiphyseal plate:

**Type I**- Slip at plate level

**Type II**- Above (proximal)

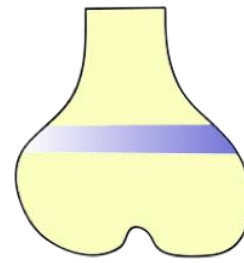
**Type III**- Lower (distal)

**Type IV**- Through Everything  
(prox and distal)

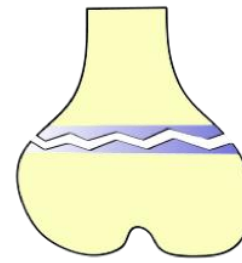
**Type V**- Rammed at plate  
level

**Tips:**

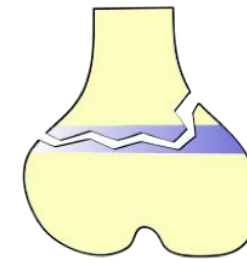
- More advanced = more likely to have growth disturbance
- I and V can have normal XR
- II is most common



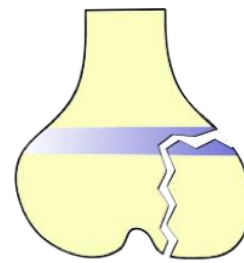
Normal



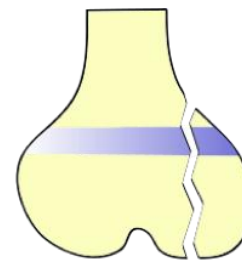
Type 1 - 5%



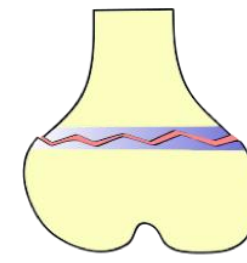
Type 2 - 75%



Type 3 - 10%



Type 4 - 10%



Type 5 - uncommon



**FOUNDATIONS CHALLENGE**  
**CLINICAL CONCEPTS**

**NAME 2 CAUSES OF JAUNDICE OCCURRING AT  
24-72HR OF LIFE?**



**FOUNDATIONS CHALLENGE**  
**CLINICAL CONCEPTS**

**NAME 2 CAUSES OF JAUNDICE OCCURRING AT  
24-72HR OF LIFE?**

**Physiologic Jaundice**

**Breast Feeding Jaundice**

**Decreased Conjugation  
(Crigler-Najjar, Gilbert's)**





**FOUNDATIONS CHALLENGE  
KNOWLEDGE BOMB**

**Neonatal Jaundice**

**Neonatal Jaundice Differential**

<b>1st 24hr</b>	<b>24-72hr</b>	<b>72hr-7days</b>	<b>&gt; 7 days</b>
<p>ABO/Rh incompatibility</p> <p>G6PD deficiency</p> <p>Hereditary spherocytosis</p> <p>Polycythemia</p> <p>Ileus or obstruction</p> <p>Infection</p>	<p>Physiologic Jaundice</p> <p>Breast Feeding Jaundice</p> <p>Decreased Conjugation: Crigler-Najjar, Gilbert's</p>	<p>Breast Feeding Jaundice</p> <p>Infection</p> <p>Congenital Infections</p>	<p>Infection</p> <p>Hepatitis</p> <p>Metabolic Disorder</p> <p>Biliary Atresia</p> <p>Breast Milk Jaundice</p>



**FOUNDATIONS CHALLENGE**  
**CLINICAL CONCEPTS**

**NAME 3 OF THE 5 CYANOTIC  
CONGENITAL HEART LESIONS.**



**FOUNDATIONS CHALLENGE**  
**CLINICAL CONCEPTS**

**NAME 3 OF THE 5 CYANOTIC  
CONGENITAL HEART LESIONS.**

**Truncus Arteriosus**

**Transposition of the Great Vessels**

**Tricuspid Atresia**

**Tetralogy of Fallot**

**Total Anomalous Pulmonary Venous Return**



What is the most common cyanotic heart lesion in a child >1 y/o?

- a. Tetralogy of Fallot
- b. ASD
- c. VSD
- d. Coarctation of the aorta
- e. Hypoplastic left heart syndrome



Which of the following typically causes myocarditis in a pediatric patient?

- a. Coxsackie A virus
- b. Rotavirus
- c. Coxsackie B virus
- d. RSV
- e. EBV



# CONGENITAL HEART DISEASE

- Blue baby
  - Cyanotic heart disease (R → L shunt)
    - $O_2\text{Sat}$  nor  $\text{PaO}_2$  do not increased with  $O_2$
- Mottled baby (gray)
  - Outflow tract obstruction with shock
- Pink baby
  - CHF (L → R shunt)



# CONGENITAL HEART DISEASE

- Cyanotic
  - Normal O2 Sat: right heart 70-75%; left heart 95-98%
  - Some lesions are duct dependent: will develop cyanosis if it closes
  - Severe left-side outflow obstruction: critical AS, hypoplastic left heart, and severe coarctation of the aorta
  - Terrible 5 T's in central cyanosis
    - TOF
    - Tricuspid atresia
    - Truncus arteriosum
    - Total anomaly pulmonary venous return (TAPVR)
    - Transposition of great arteries vessels (TGA)
    - Stenosis pulmonary or atresia



# CONGENITAL HEART DISEASE

## ▪ Presentation

- Generalized or central cyanosis
- Signs of shock: poor distal perfusion, cool extremities, weak cry, tachycardia
- Quiet tachypnea ± respiratory distress

## ▪ Evaluation

- Central vs peripheral
- O<sub>2</sub> challenge (hyperoxia test): 100% O<sub>2</sub> by face mask; in cyanotic heart disease PaO<sub>2</sub> will only increase slightly (<100 mm Hg)
- CXRay
  - Look for abnormality of heart shape
  - Increased pulmonary vascularity: TAPVD, Truncus, TGA
  - Decreased pulmonary vascularity: TOF, Ebstein's anomaly, hypoplastic right heart
- ECG
- ABG
- Echo 2D





# CONGENITAL HEART DISEASE

- CHF

Age	Disease
1 min	Noncardiac origin: anemia, acidosis, hypoxia, hypoglycemia, hypocalcemia, sepsis
1 hour	
1 day	PDA in premature infants
1 week	HPLV
2 weeks	Coarctation
1 month	VSD
3 months	SVT
1 year	Myocarditis, cardiomyopathy, severe anemia
10 years	Rheumatic fever

} Acquired

} Congenital

} Acquired



# CONGENITAL HEART DISEASE

- Murmur/symptomatic patient
  - Shunts: VSD, PDA, ASD
  - Obstruction
  - Valvular incompetence



# CONGENITAL HEART DISEASE

- Abnormal pulses
  - Bounding
    - PDA, AI, AVM
  - Decreased with prolonged amplitude
    - Coarctation, HPLV
- Hypertension
  - Coarctation



# CONGENITAL HEART DISEASE

- Syncope
  - Cyanotic
    - TOF
  - Acyanotic
    - Critical AS



# CONGENITAL HEART DISEASE

- “Acyanotic”
  - May present with CHF or heart murmur
  - Lesions with increased pulmonary vascularity: ASD, VSD, PDA, AVSD
  - Lesions with decreased pulmonary vascularity: AS, PS, coarctation
- Peripheral cyanosis
  - PDA
  - VSD
  - ASD



What is the most common cyanotic heart lesion in a child >1 y/o?

- a. Tetralogy of Fallot
- b. ASD
- c. VSD
- d. Coarctation of the aorta
- e. Hypoplastic left heart syndrome



# CYANOTIC HEART DISEASES: 5 TYPES

## TERRIBLE 5 T'S IN CENTRAL CYANOSIS

- Use your five fingers:
  - 1 finger up: Truncus Arteriosus (1 vessel)
  - 2 fingers up: Dextroposition of the Great Arteries (2 vessels transposed)
  - 3 fingers up: Tricuspid Atresia (3=Tri)
  - 4 fingers up: Tetralogy of Fallot (4=Tetra)
  - 5 fingers up: Total Anomalous Pulmonary Venous Return (5=5 words)



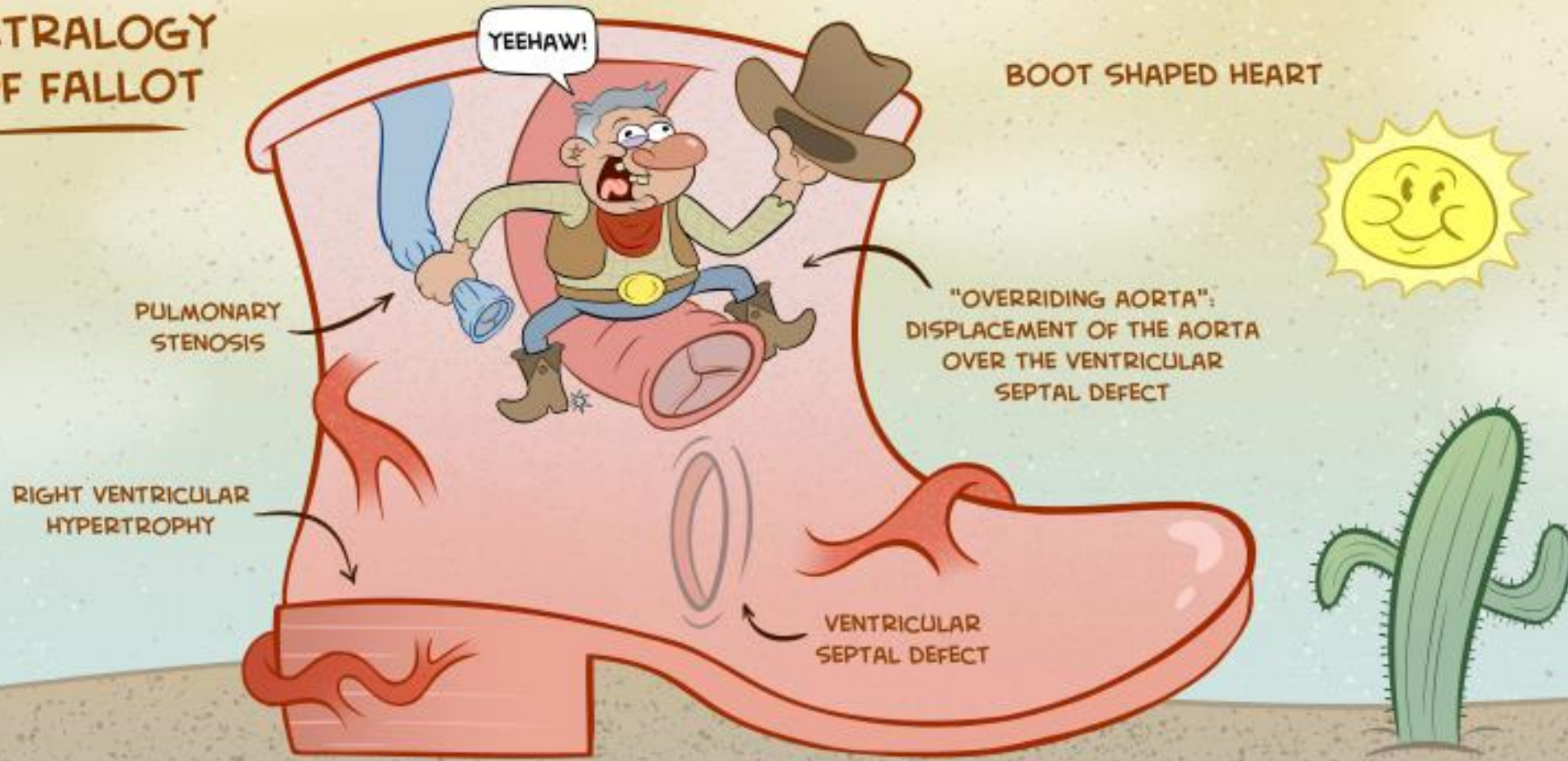
# CONGENITAL HEART DISEASE

- Tetratology of Fallot (TOF)
  - Pulmonary stenosis
  - RVH
  - VSD
  - “Overriding” aorta
- Treatment
  - Position
  - Oxygen
  - Morphine





# TETRALOGY OF FALLOT



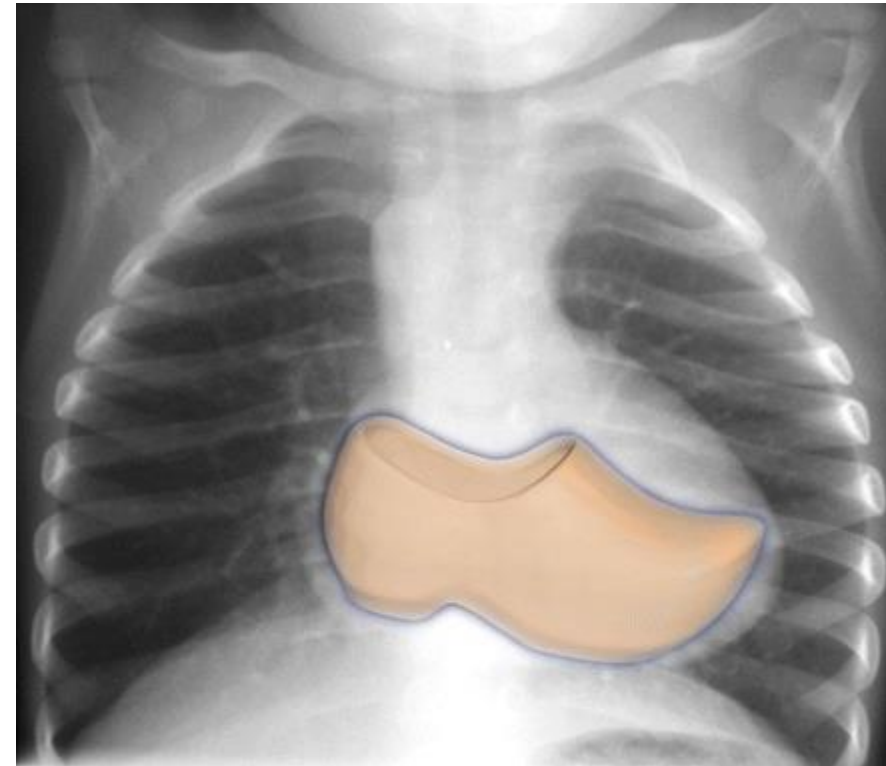
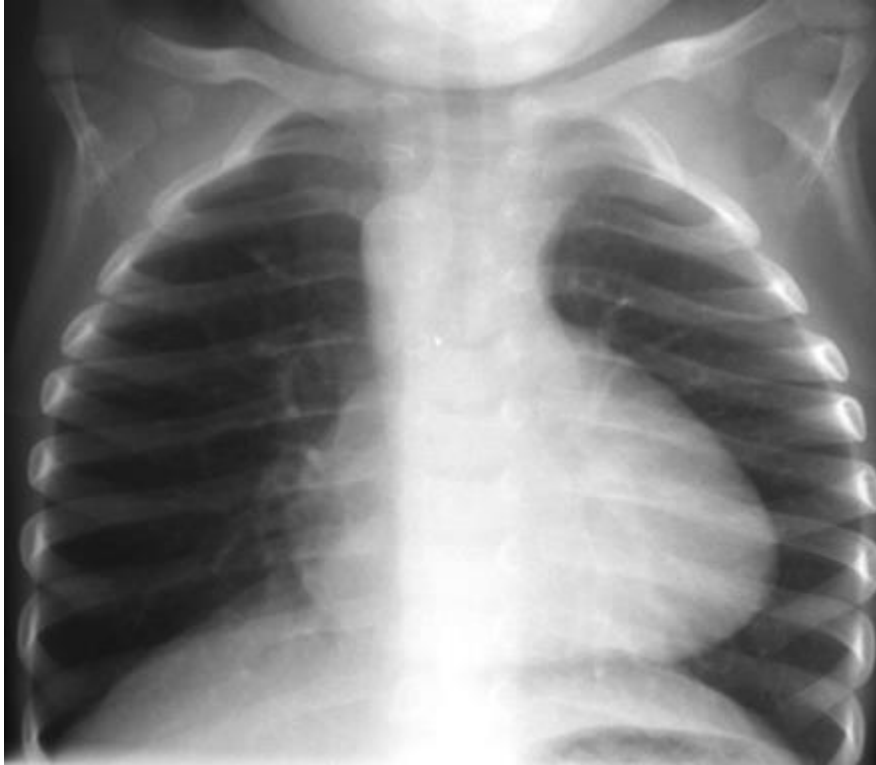[www.medcomic.com](http://www.medcomic.com)

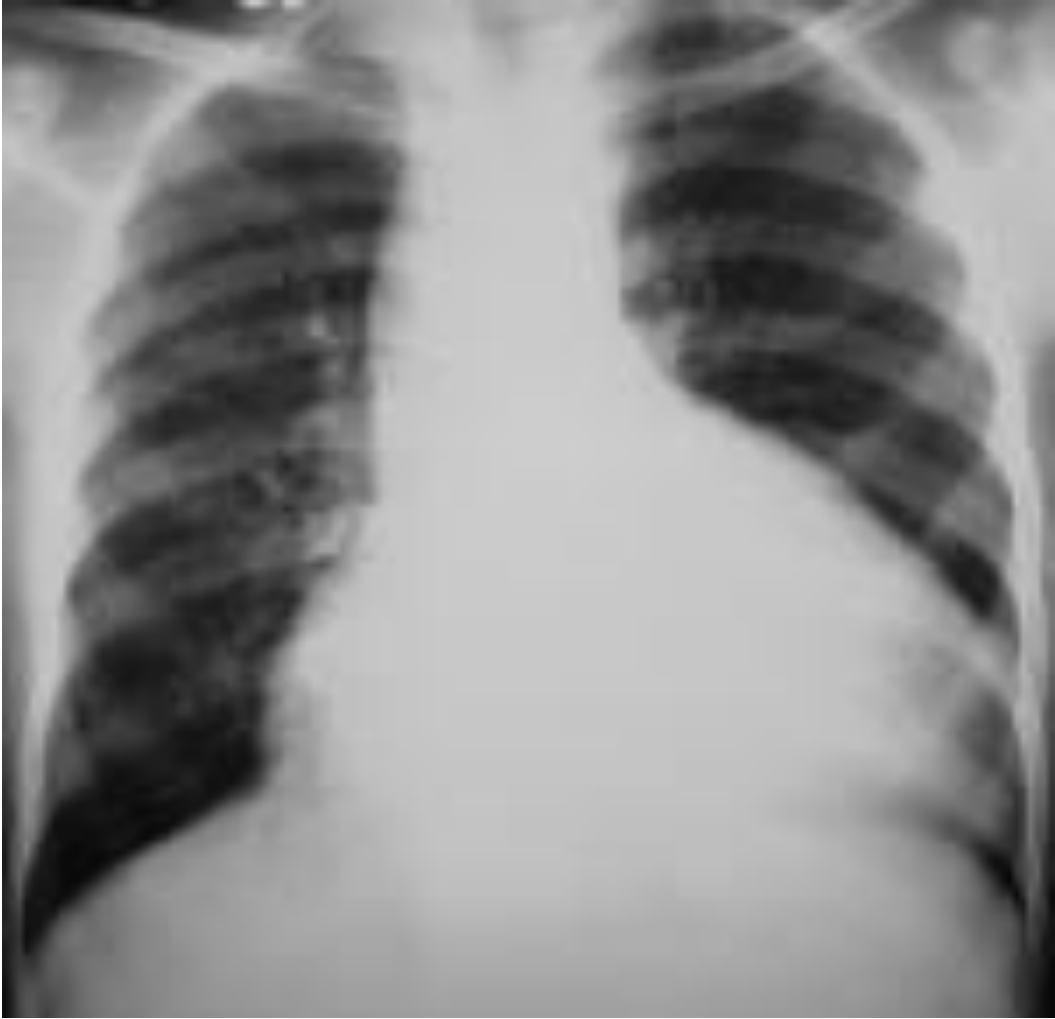© 2013 Jorge Muniz



# TOF

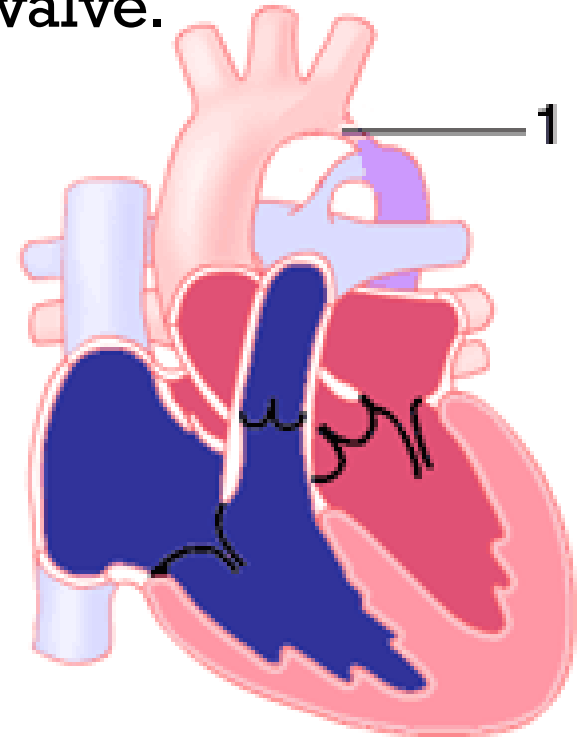
- PA chest radiograph shows normal heart size which is "boot-shaped" (from *coeur-en-sabot*, literally translated *boot shaped*). There are diminished pulmonary vascular markings and a prominent left sided aortic arch (indentation in left of trachea).





# COARCTATION OF THE AORTA (COA)

- More common in males
- Almost always juxtaductal
- 85% of children with CoA have a bicuspid aortic valve.
- Symptoms and Signs:
  - SEVERE : Shock
  - MODERATE : CHF
  - MILD : Headaches, leg claudication



# COA: SYMPTOMS AND SIGNS

- Decreased femoral pulses are an important sign
  - Especially in neonates.
- BP lower in the lower limbs
- Clinical manifestations vary from congestive heart failure in infancy to hypertension with differential pressures between the upper and lower extremities in adulthood



# COA: TREATMENT → NEWBORN

- In a critically ill newborn, the goals of management are to improve ventricular function and restore blood flow to the lower body.
  - A continuous intravenous medication, prostaglandin (PGE-1), is used to open the ductus arteriosus (and maintain it in an open state) allowing blood flow to the body beyond the coarctation.
  - It is also often necessary to begin intravenous medications that improve the contraction of the heart muscle.
  - Will almost always need to be placed on a ventilator before surgery.
- In symptomatic newborns with coarctation, surgical repair is usually done on an urgent basis following initial stabilization.
  - Rarely, an infant will not improve with medical therapy and surgery must proceed before the infant has been stabilized.

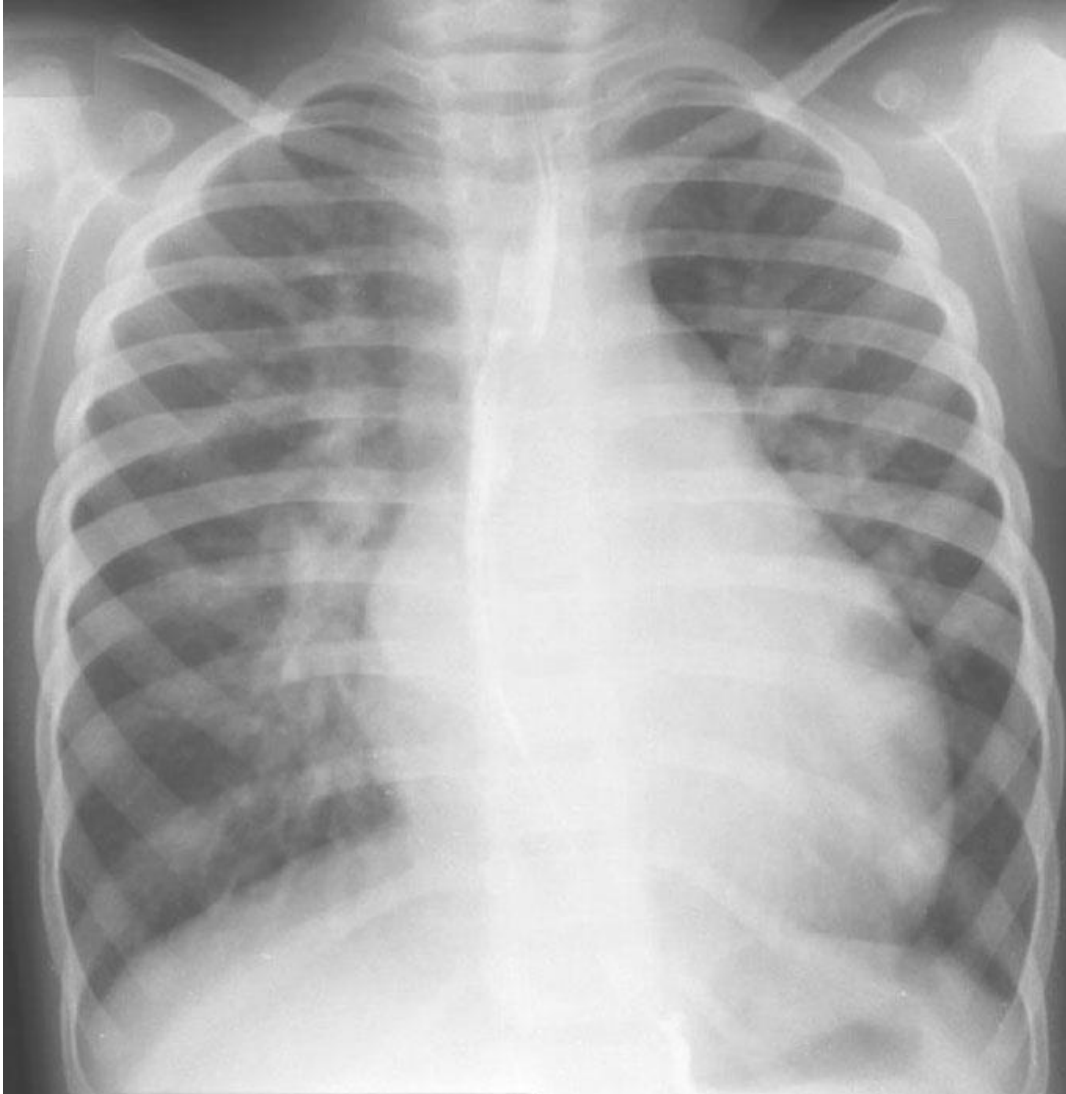


# COA: TREATMENT → OLDER CHILD

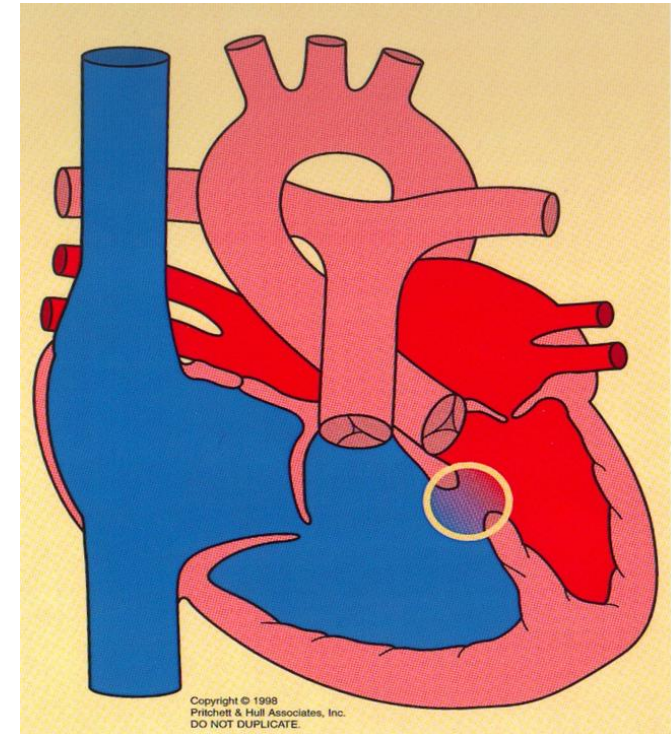
- Because older children may have minimal symptoms, coarctation repair is typically planned electively.
- In older children, an alternative to surgery may be catheter-based therapy.
  - In selected cases, the area of narrowing may be dilated with a balloon. In some patients the coarctation can be treated very effectively with the placement of a metal stent.
  - Because stents don't grow, this therapy is typically used in older, larger patients.
  - The availability of covered stents, investigational in the United States, will probably enhance the safety and effectiveness of coarctation stenting in the future.



# VSD



- PA chest radiograph demonstrates cardiomegaly, the pulmonary outflow tract is convex, and the pulmonary arterial markings are increased





# VENTRICULAR SEPTAL DEFECTS ( VSD)

- This is the most common form of CHD
- The VSDs are subdivided according to the part of the septum they occur in : Muscular, perimembranous, inlet, outlet
- A large VSD causes left ventricular enlargement
- With a small VSD there is normal growth and development
- With a large defect there may be CHF( usually at 6-8 weeks), pulmonary infections and delayed growth



# VSD: SYMPTOMS AND SIGNS

- Loud 4-5/6 , harsh holosystolic murmur, middiastolic rumble and a loud P2
- Babies who do have moderate or large ventricular septal defects with excessive blood flow to the lungs will have signs of congestive heart failure.
  - The most important sign will be the baby's growth.
  - Will have failure to thrive and will have difficulty maintaining a normal weight gain in the first few months of life.
- If a baby grows well in the first few months, it is likely that the ventricular septal defect will not lead to congestive heart failure and the baby can be observed. If the baby does show significant signs of congestive heart failure, the ventricular septal defect may need to be surgically closed.



# VSD

- EKG: LVH or BVH
- ECHO: Diagnostic



# VSD

- Natural history : Small VSDs close spontaneously depending on the site.
- Unrepaired the large defects may lead to Eisenmenger's syndrome.



# VSD

- Many times, observation is the only treatment needed, with regular checkups with the cardiologist.
- Diuretics, digoxin and afterload reducing agents are used prior to surgery - if needed.

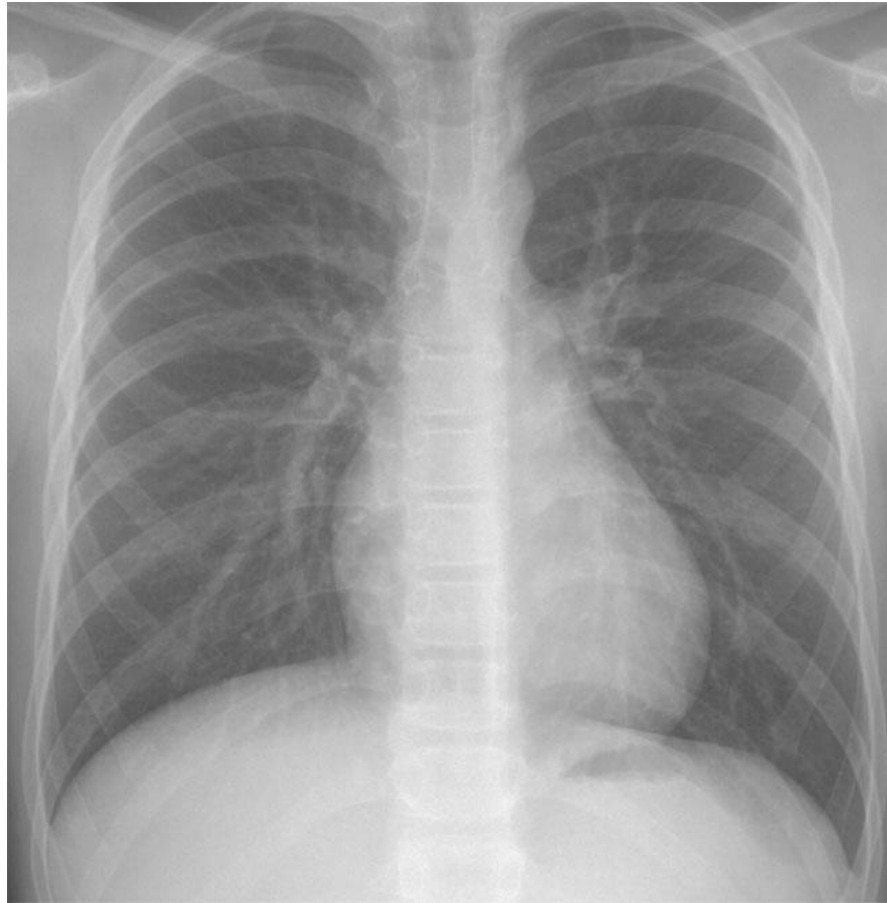


# VSD

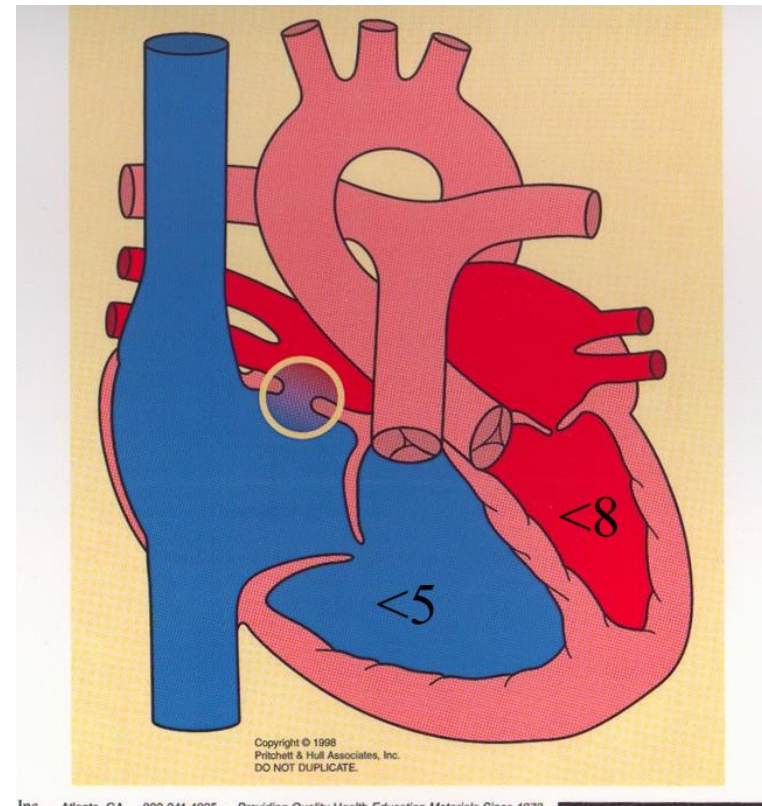
- Sometimes babies get so worn out with feeding that a small tube through the nose and into the stomach is temporarily necessary to deliver the food. The goal is to control the symptoms of heart failure to allow the baby time to grow.
  - In the meantime, the ventricular septal defect may get smaller and cause fewer problems, in which case the infant will not require surgery and will eventually not need medications.
- When the symptoms of a ventricular septal defect are hard to control with medicines or the baby is unable to grow, surgical closure of the defect is often recommended.
- Surgical closure of isolated ventricular septal defects is uncomplicated in 99% or more of cases.



# ATRIAL SEPTAL DEFECT



- Posteroanterior (PA) chest radiograph demonstrates a slight increase in pulmonary arterial markings with a normal sized heart. The main pulmonary artery segment is convex



# ATRIAL SEPTAL DEFECTS (ASD)

- Three types exist : primum, secundum and sinus venosus
- The most common is the *secundum* type





# ASD: SYMPTOMS AND SIGNS

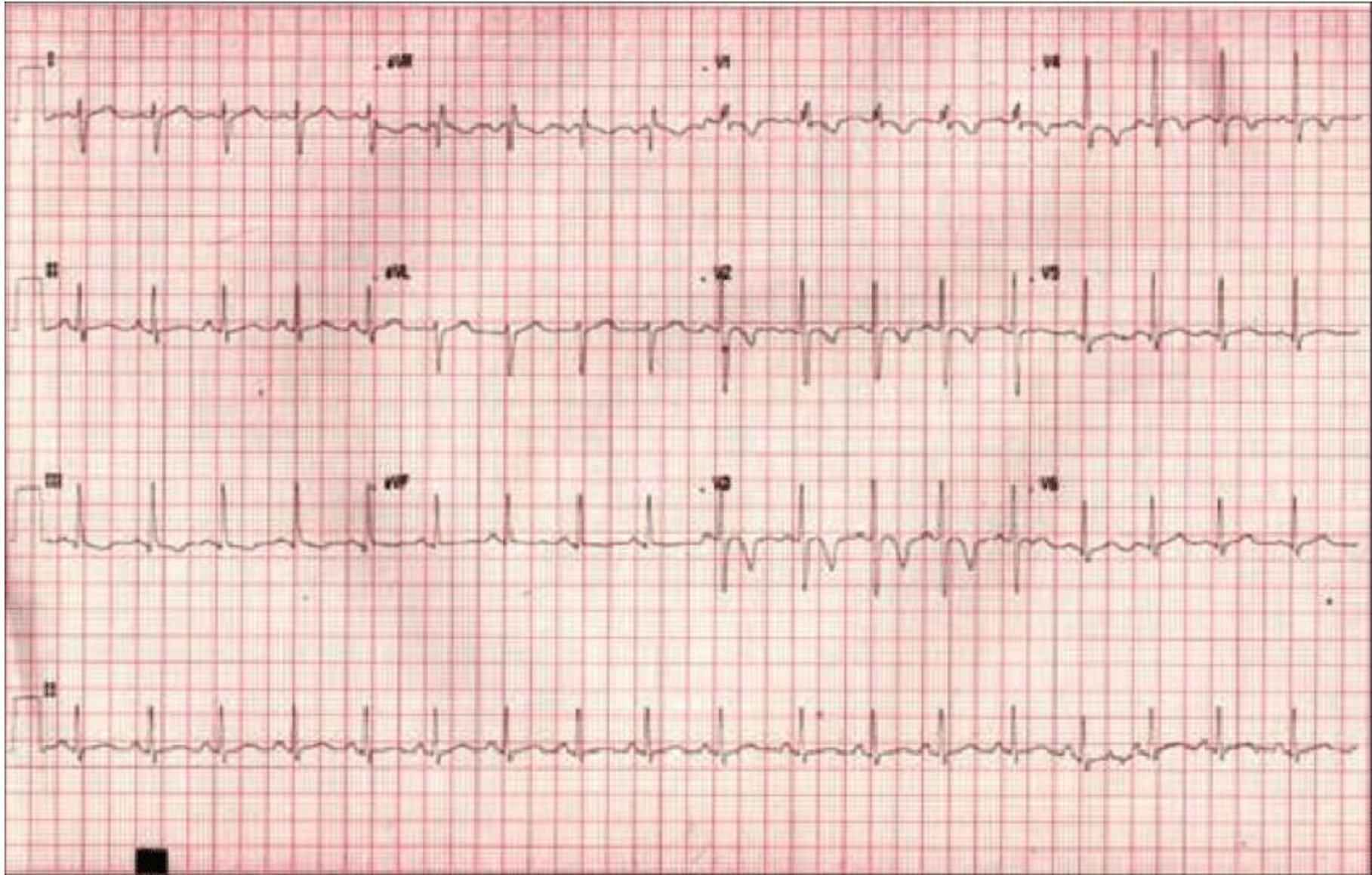- In most children, atrial septal defects cause no symptoms.
- A very large defect may allow so much blood flow through it to cause congestive heart failure symptoms such as shortness of breath, easy fatigability, or poor growth, but this is uncommon.
- The murmur doesn't actually come from blood going across the hole, but rather from the pulmonary valve area because the heart is forcing an unusually large amount of blood through a normal sized valve.
- The second heart sound is characteristically "split" which is different than what is heard when listening to a normal heart
  - 2-3/6 SEM at the ULSB and a fixed wide split S2



# ASD

- A large ASD causes right ventricular enlargement
- Natural History: Arrhythmias and pulmonary obstructive vascular disease in the 3rd and 4th decade.
- EKG: RAD and IRBBB
- ECHO: Diagnostic



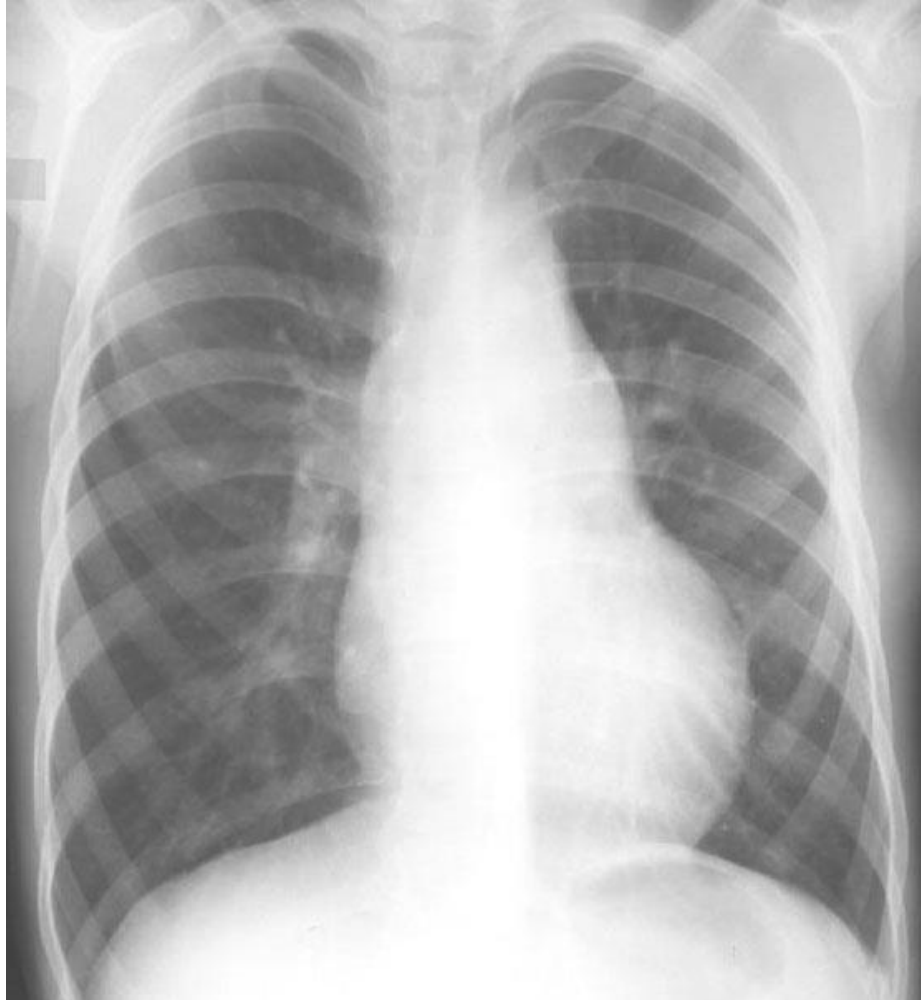

# ASD: TREATMENT

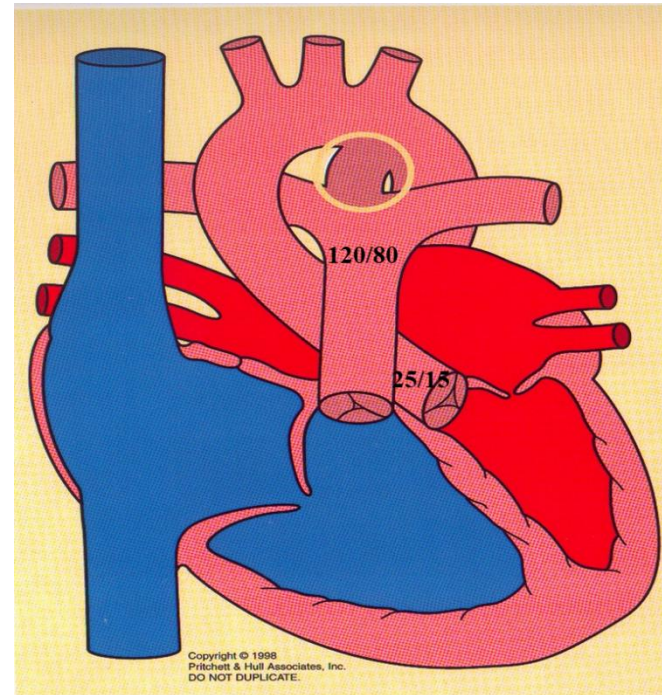
- In some children, an ASD may close on its own without treatment.
- Although an atrial septal defect may be closed by [open-heart surgery](#), this approach is not as common as it once was now that transcatheter closure devices are readily available.
- Following closure of an atrial septal defect, there should be no problems with physical activity and no restrictions. Regular follow-up appointments will be made with a cardiologist; regardless of closure mode, mid-term and late problems can occur.



# PATENT DUCTUS ARTERIOSUS



- The heart is slightly enlarged, the main pulmonary artery convex, and the aortic arch prominent above the MPA. There are increased pulmonary vascular markings.



# PDA

- Persistent patent ductus arteriosus occurs in 1 in 2500 to 1 in 5000 live births and represents between 9-12% of all congenital heart defects. There is a 2:1 female to male ratio.
- Associations: Infants of prematurity, patients exposed to hypoxemia, birth at high altitudes, female sex and exposure to rubella particularly in the first 4 weeks of pregnancy are all associated with an increased incidence.



# PDA: SYMPTOMS AND SIGNS

- If small
  - No symptoms
  - May be detected only upon further evaluation of a heart murmur.
- After birth, the pressures and resistance are much tighter in the aorta than the pulmonary artery, so if a ductus arteriosus is present, blood will flow from the aorta into the pulmonary artery. This extra blood flow into the lungs can overload the lungs and put an additional burden on the heart to pump this extra blood.



# PDA: SYMPTOMS AND SIGNS

- The classical findings are diagnostic.
  - The pulses are bounding.
  - The blood pressure has a wide pulse pressure.
  - The apex beat may be displaced.
  - There is a LV impulse.
  - The second heart sound is loud and widely split with a "slap-sail" quality.
  - The murmur is characteristically continuous, or machinery like in quality. The diastolic component may disappear as one move down the sternum, particularly in smaller infants.
- If large can cause CHF at 6-8 weeks in a term infant





# PDA: TREATMENT

- In a newborn, the patent ductus arteriosus still has the potential to close on its own without intervention. Thus, in newborns, additional time may be allowed for the patent ductus arteriosus to close on its own if the heart failure can be easily managed.
  - Usually closes in the first 2 weeks of life.
  - If symptoms are severe, such as in a premature infant, or if it is felt that it is unlikely to close on its own, however, medical or surgical closure is pursued.
- If a patent ductus arteriosus is still present beyond the newborn period, it will generally never close on its own. Closure is recommended in such cases to prevent the future risk of endocarditis.



# PDA: TREATMENT

- In newborns, a medication such as indomethacin or ibuprofen can be given.
  - These medications are given in the stomach and can constrict the muscle in the wall of the patent ductus arteriosus and promote closure.
  - These drugs do have side effects, however, such as kidney injury or bleeding, so not all babies can receive them. Because of the potential side effects, the baby must have lab values checked before medications can be given. If the lab values are not normal or if the medications do not work, surgery can be performed and the patent ductus arteriosus tied off (ligated).
- Medications are generally only successful in newborns. In older infants and children, options for closure include surgery or closure in the cardiac catheterization laboratory with a device or coil.



# PEDIATRIC ECG INDICATIONS



# “PEDS ECG” + 3 F’S

- **P**- Pericarditis (or myocarditis), post cardiac surgery
- **E**-Exertional symptoms
- **D**-Drugs, disease (Kawasaki), dysrhythmia
- **S**-Syncope/seizure
- **E**-Electrolyte disturbance
- **C**-Cyanosis, contusion (myocardial), cold (hypothermia)
- **G**- ConGenital heart defects
- **3 F’s**:
  - Fever (rheumatic)
  - Failure (heart)
  - Family



# CHEST PAIN IN KIDS

- Rarely cardiac in origin
- ECG NOT usually helpful in diagnosis
- Consider ECG for parent reassurance



# CHEST PAIN IN KIDS – WHEN TO WORRY?

- First degree relative with sudden death or cardiomyopathy
- Pathologic murmur on exam
- Pericardial rub
- Hepatomegaly
- Peripheral edema
- Occurs during exercise
- History of heart disease
- Patients with Marfan, Turner, Ehlers-Danlos syndrome



# AGE RELATED CHANGES IN NORMAL ECG'S



- Heart development during infancy and childhood causes differences in HR, interval durations, and ventricular dominance
- Normal adult ECG features may be abnormal age-related changes in pediatrics





# **PEDIATRIC ECG FINDINGS THAT MAY BE NORMAL**

- HR > 100 bpm
- Short P wave and short QRS duration
- Short PR and QT intervals
- RAD
- Dominant R precordial R waves
- Right precordial T wave inversion
- Inferior and lateral Q waves



# RESTING HR

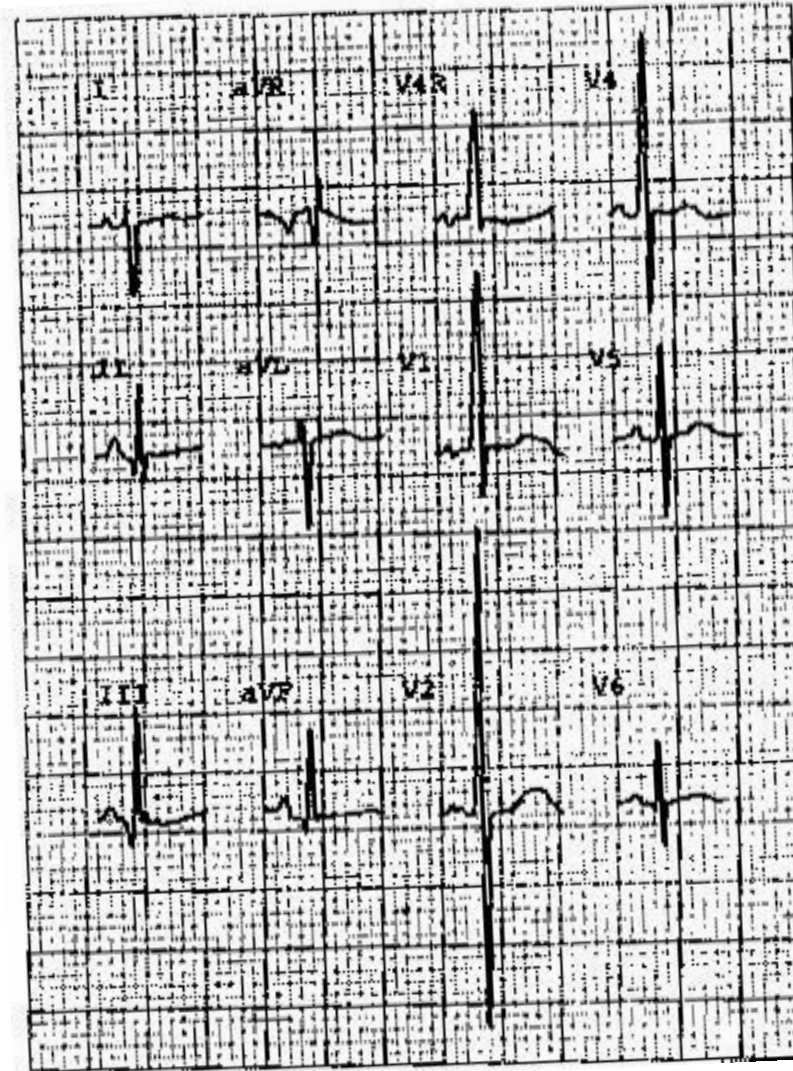
- Birth 140 bpm
- 1 yr: 120 bpm
- 5 yr: 100 bpm
- 10 yr: adult values



# T WAVES

- T wave in V1 inverts by 7 days, stays inverted until 7+ years
- Upright T waves in right precordial leads (V1-V3) between 7d and 7yrs are ABNORMAL, usually RVH
- Inverted T waves in V1 and V2 can persist into adolescence
  - Persistent Juvenile Pattern





RAD

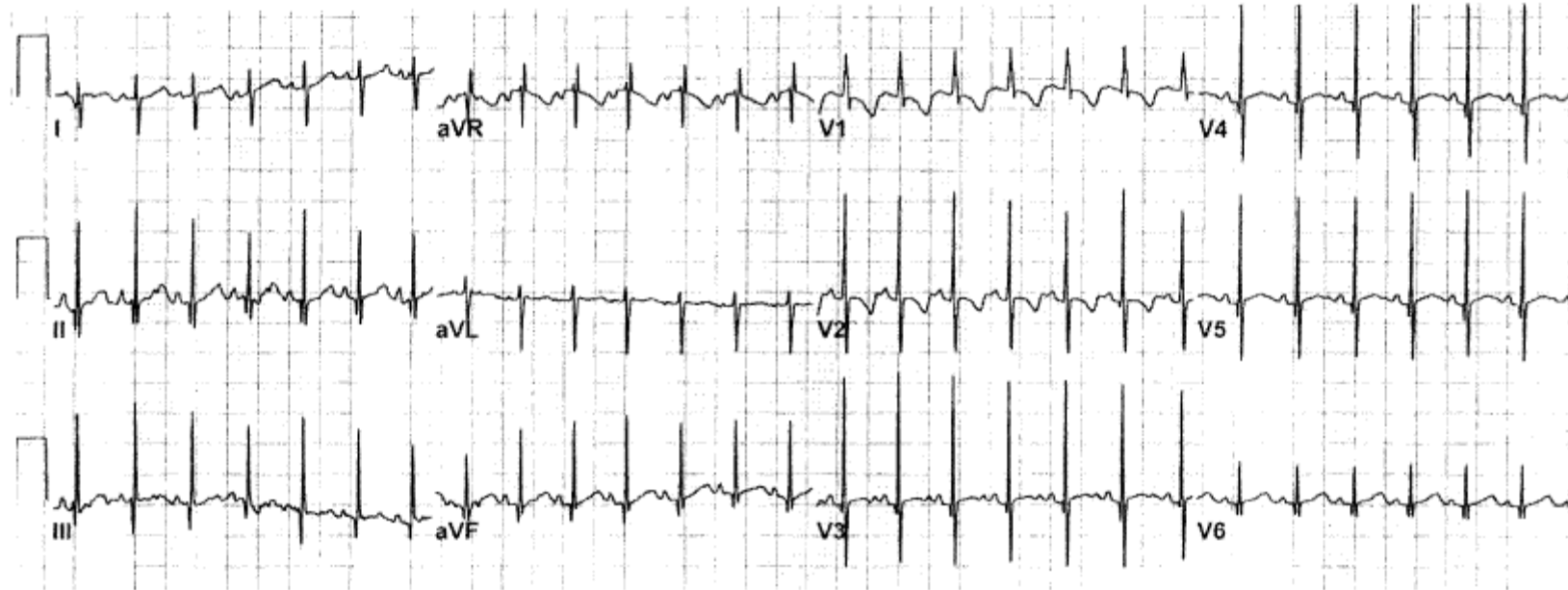
Dominant R in  
right precordial  
leads

Upright T in V1

**3-DAY-OLD**



# 4-WEEK-OLD INFANT



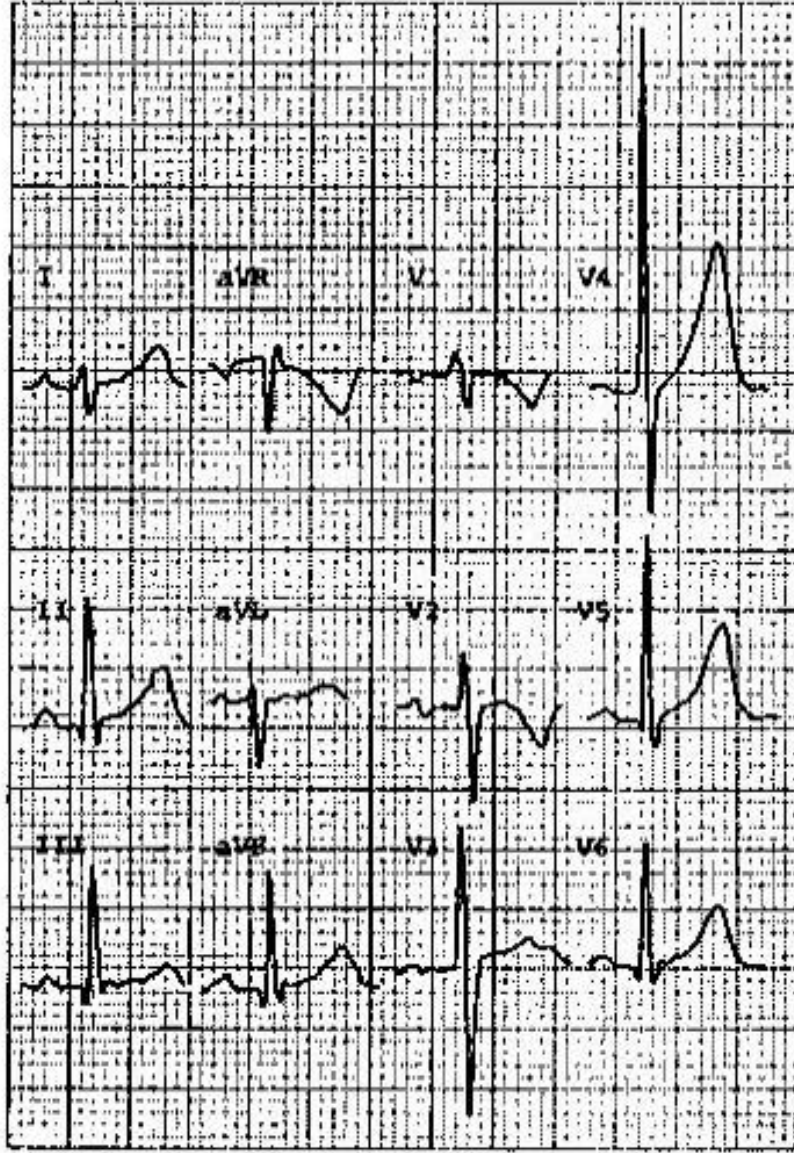
RAD

Right ventricular dominance

Inverted T waves in V1 and V2



Normal adult axis  
Left ventricular  
dominance  
Inverted T-waves  
(Juvenile Pattern)



**9-YEAR-OLD**



# QT INTERVAL

- Depends on age and HR
  - As age increases QT increases; as HR increases QT decreases
  - < 6 months – 0.49 sec or less
  - >6 months – 0.45 sec or less
- Important in recognition of congenital prolonged QT syndrome
- Can also prolong QT interval
  - (hypoK<sup>+</sup>, hypoCa<sup>++</sup>, digitalis, quinidine, procainamide, Li<sup>+</sup>, tricyclics, phenothiazines, ERN, organophosphates, ARF, hypothermia, myocarditis)



# PEDIATRIC ARRHYTHMIAS



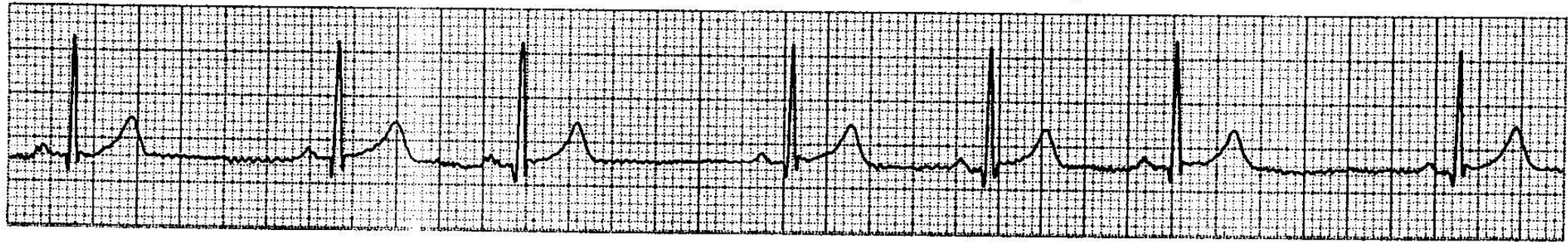


# PEDIATRIC ARRHYTHMIAS

- Most common pediatric dysrhythmias: SVT, sinus bradycardia, sinus tachycardia, and sinus arrhythmia
- AFib, atrial flutter, VT, or VF rare
- **BUT**: kids with congenital heart disease may have any arrhythmia



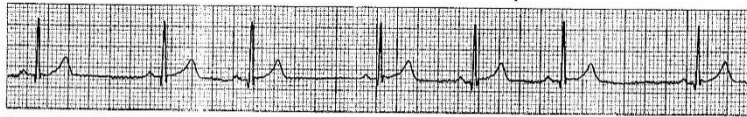# WHAT SHOULD BE DONE ABOUT THIS ECG?



Electrocardiogram from 9 year old boy showing marked sinus arrhythmia, a common finding in paediatric traces

# NOTHING!

- Sinus arrhythmia common in children's ECGs
- Often quite marked



Electrocardiogram from 9 year old boy showing marked sinus arrhythmia, a common finding in paediatric traces



# SINUS ARRHYTHMIA

- **Inspiration:** increased blood flow to heart  
decreases vagal tone: increased HR
- **Expiration:** increased vagal tone: lower HR
- Rarely in infants but normal in many kids/athletes; generally insignificant



# SINUS BRADYCARDIA

- Sinus rate below normal for age: 80 in newborn is sinus bradycardia; 50 in athletic teenager is normal
- Common in severe distress: **hypoxia**\*/drugs
- Can be asymptomatic/insignificant (i.e. sleep/well-conditioned), treat if signs of poor systemic perfusion



# SINUS TACHYCARDIA

- Narrow QRS
- P wave precedes every QRS complex
- HR varies with activity
- Beat-to-beat variability
- Usually <200 in infants
- Usually <180 in children
- ST usually physiologic: fear, fever, hypovolemia



# SVT

- Most common symptomatic arrhythmia in infants and children
  - Peak incidence is around 2 months
- Can occur in healthy infants and children
- Vague history: irritable, pallor, lethargic, feeding poorly, may present with signs of CHF
- Regular rhythm  $> 220$  (infants up to 280-320)
- SVT rate is constant; consider very fast ST if rate rises/falls



# TREATMENT FOR SVT

- Stable
  - Vagal maneuvers
  - Adenosine
- Unstable
  - Cardioversion
    - 0.5-1 J/kg
- Remember
  - WPW present in 10-20% of SVT cases
  - If wider complex or known WPW
    - Consider Procainamide 15 mg/kg





# SVT

- **Infant**

- > 220 BPM

- **Child**

- > 180 BPM

- **Treatment**

- Vagal maneuvers
- Adenosine: 0.1 mg/kg (max. 6 mg), repeat dose at 0.2 mg/kg (max. 12 mg)
- Cardioversion: 0.5 J/kg – 1 J/kg if unstable



**FOUNDATIONS CHALLENGE**  
**CLINICAL CONCEPTS**

**VIRAL EXANTHEM MATCH-UP**

**Measles/Rubeola**

**Petechiae on hard palate,  
rash x3d head -> trunk**

**Rubella**

**High fever then rash**

**Erythema Infectiosum**  
(Parvovirus B19)

**Vesicles at different stages**

**Varicella**

**“Slapped” cheeks**

**Roseola**

**Koplik’s spots  
Cough, coryza, conjunctivitis**



**FOUNDATIONS CHALLENGE**  
**CLINICAL CONCEPTS**

**VIRAL EXANTHEM MATCH-UP**

**Measles/Rubeola**

**Koplik's spots**  
**Cough, coryza, conjunctivitis**

**Rubella**

**Petechiae on hard palate,**  
**rash x3d head -> trunk**

**Erythema Infectiosum**  
**(Parvovirus B19)**

**"Slapped" cheeks**

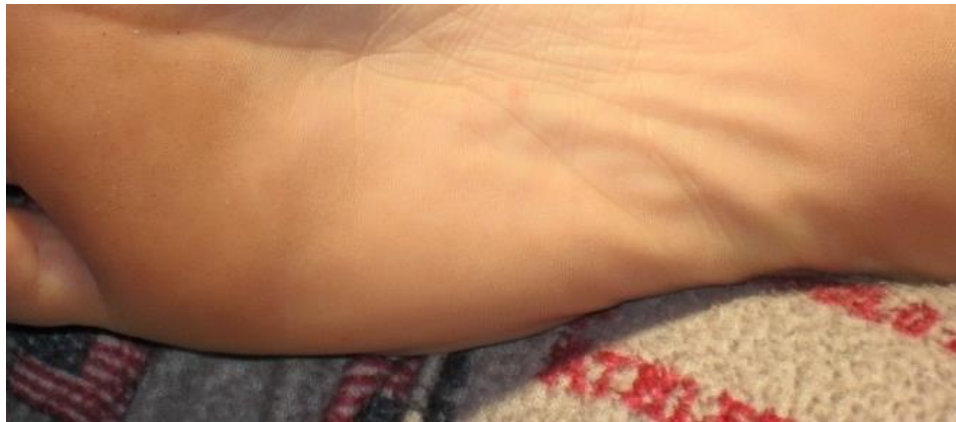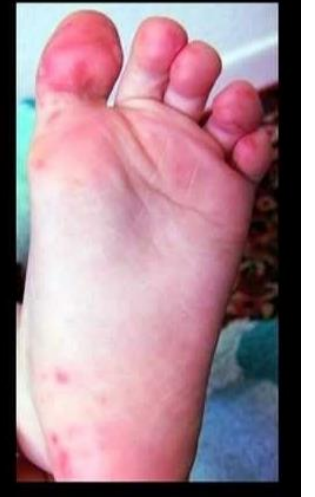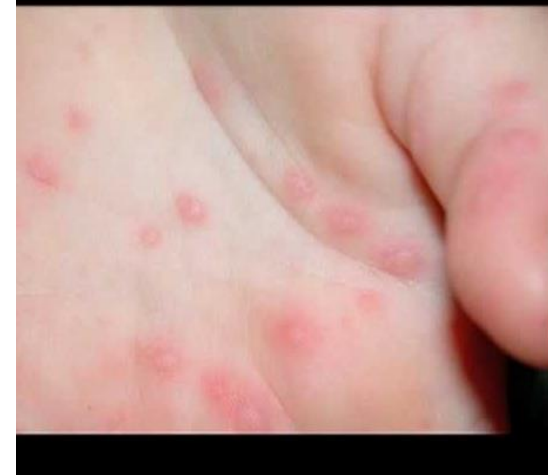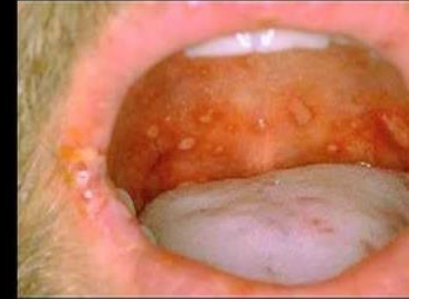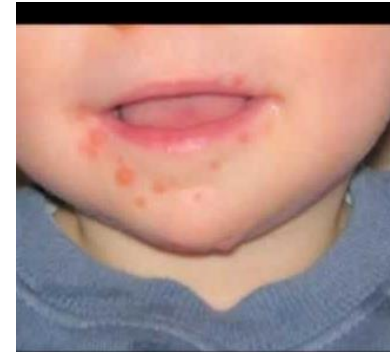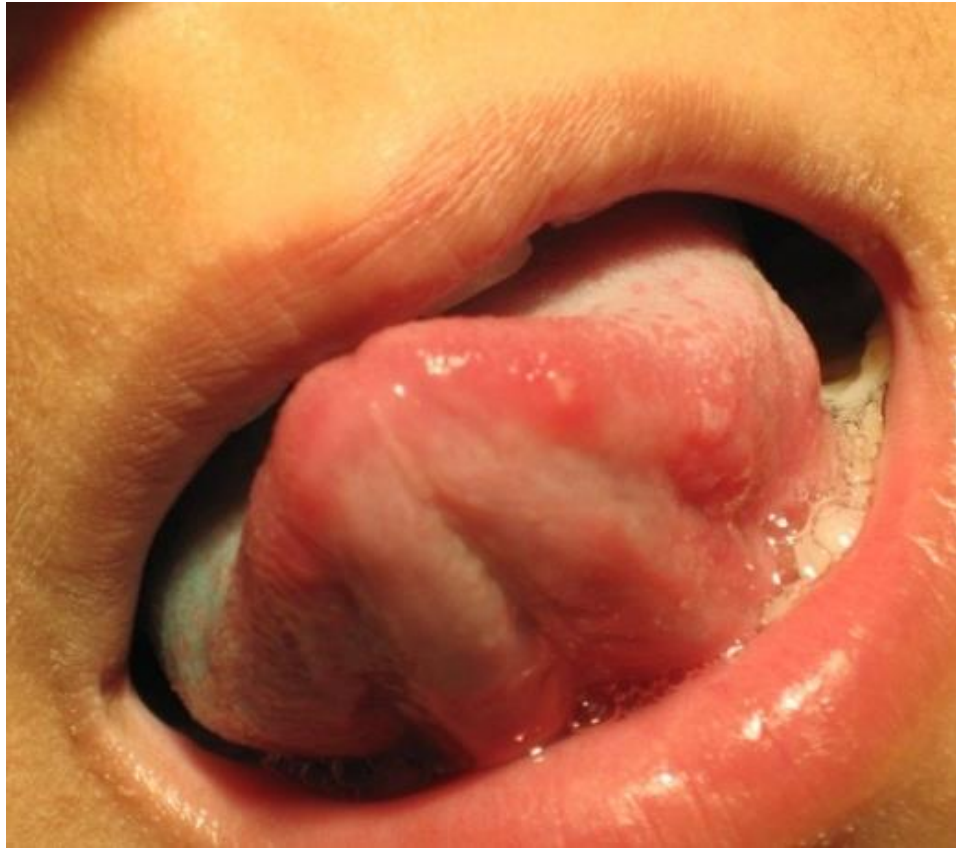**Varicella**

**Vesicles at different stages**

**Roseola**

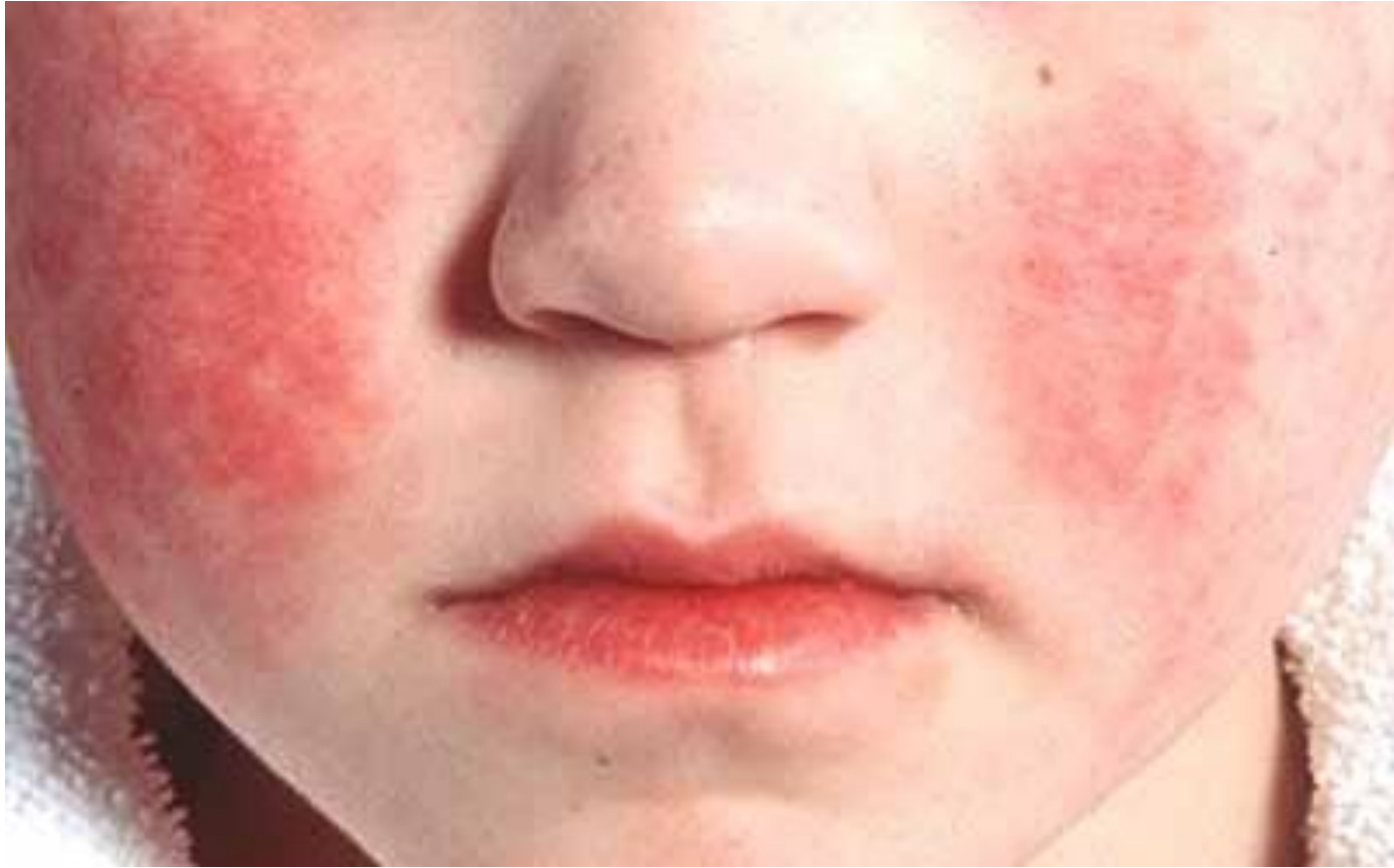**High fever then rash**





# HAND-MOUTH-FOOT DISEASE

Coxsackie A16



# **FIFTH DISEASE**

Parvovirus B19



# RUBEOLA

ORDINARY MEASLES



CONJUNCTIVITIS  
COUGH  
CORYZA  
FEVER

KOPLIK SPOTS ON  
BUCCAL MUCOSA

RASH  
APPEARS  
AT THE  
HAIRLINE  
AND  
SPREADS  
CEPHALOCAUDALLY  
OVER 3 DAYS

# RUBELLA

GERMAN MEASLES



HEADACHE  
LOW GRADE FEVER  
SORE THROAT  
CORYZA

FORCHHEIMER SPOTS  
ON SOFT PALATE

LYMPHADENOPATHY

RASH BEGINS  
ON THE FACE  
AND SPREADS  
CEPHALOCAUDALLY

# ROSEOLA INFANTUM

EXANTHEM SUBITUM



AFFECTS YOUNG CHILDREN  
6-36 MONTHS OLD

CAUSED BY  
HUMAN HERPES  
VIRUS 6

ABRUPT HIGH FEVER

AFTER FEVER SUBSIDES,  
A RASH DEVELOPS, STARTING  
ON THE NECK AND TRUNK  
AND SPREADING TO THE  
FACE AND EXTREMITIES



# RHEUMATIC FEVER

INFLAMMATORY DISEASE INVOLVING THE JOINTS, HEART, SKIN, AND NERVOUS SYSTEM AFTER AN EPISODE OF UNTREATED GROUP A STREPTOCOCCAL PHARYNGITIS

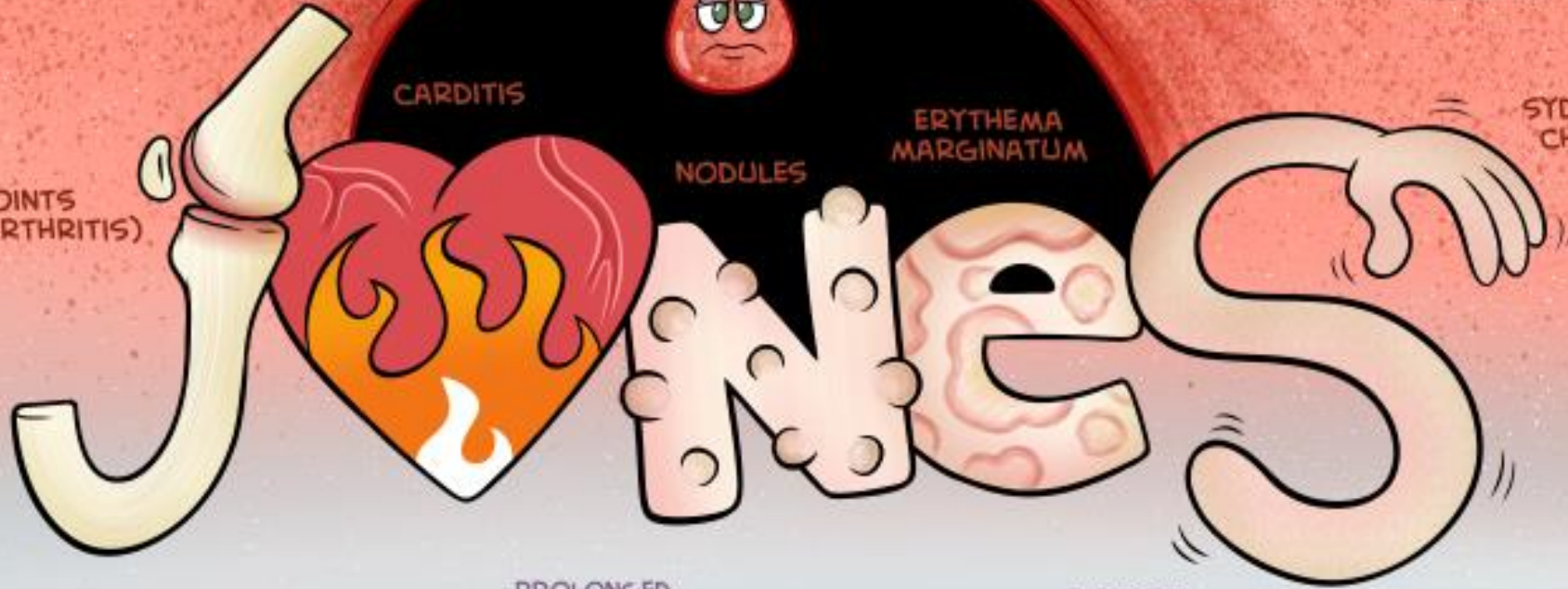
JOINTS (POLYARTHRITIS)

CARDITIS

NODULES

ERYTHEMA MARGINATUM

SYDENHAM CHOREA



ARTHRALGIA

PROLONGED PR INTERVAL

FEVER

ELEVATED ESR/CRP

■ MAJOR  
■ MINOR

JONES CRITERIA FOR DIAGNOSIS: 2 MAJOR OR 1 MAJOR AND 2 MINOR WITH EVIDENCE OF RECENT GROUP A STREP INFECTION

www.medcomic.com

© 2014 Jorge Muniz



The etiologic agent of bronchiolitis is?

- a. Adenovirus
- b. Influenza
- c. Echovirus
- d. Respiratory syncytial virus





A 2 y/o previously healthy child presents with the sudden onset of stridor at 1 A.M. The child does not have any drooling, history of foreign body, or preexisting medical condition. The most likely etiologic agent is?

- a. *S. aureus*
- b. *H. influenza*
- c. *Streptococcus*
- d. Parainfluenza
- e. Adenovirus



# COUGH

- Asthma
- Croup
  - Stridor in infant to 5 y/o; Parainfluenza
  - Racemic epinephrine, Decadron IM
- Bronchiolitis
  - Wheezing in infant to 3 y/o; RSV
  - Albuterol, steroids
- Reactive airway disease
  - Febrile with URI and wheezing
- Laryngotracheomalacia
  - Stridor in neonates
- URI
- Foreign body



# PNEUMONIA

- Neonates
  - *Group B streptococcus, Listeria, Chlamydia, and E. coli*
  - ToRCH
- 1 month/old to 5 y/o
  - *S. pneumoniae* and *H. influenzae*
  - RSV, parainfluenza, adenovirus
- > 5 y/o
  - *S. pneumoniae, Mycoplasma pneumoniae* and influenza virus



- An afebrile infant six weeks of age presents to the ED with a staccato cough, history of conjunctivitis and progressive subacute interstitial pneumonia. The most likely etiologic agent is:
  - a. *C. trachomatis*
  - b. Group B strep
  - c. *E. coli*
  - d. *Mycoplasma*



**FOUNDATIONS CHALLENGE**  
**CLINICAL CONCEPTS**

**NAME 2 FEATURES OF  
SIMPLE FEBRILE SEIZURES.**



**FOUNDATIONS CHALLENGE**  
**CLINICAL CONCEPTS**

**NAME 2 FEATURES OF  
SIMPLE FEBRILE SEIZURES.**

**6mos-6yrs**

**Single Episode**

**Fever**

**Generalized**

**< 15 min**

**Normal Exam**



- Newborn 6 weeks old that turned blue while feeding and choking in formula
- PE: WNL
- DX ?



# ALTE / BRUE

- Apparent Life-Threatening Event / Brief Resolved Unexplained Event
- Difficult to define
- Presents as an acute event that is:
  - Frightening by the observer
  - Has a defined onset and offset
  - Combination of apnea, color change, marked change in muscle tone, choking, and/or gagging
- Often the infant will recover and appear normal when seen by EMS or at ER
- Description given by frightened caregivers
- Most common < 12 months with a mean age of 13 weeks





# B R U E

- **History:**
  - Smoking: 60% someone is smoking in the house
  - Idiopathic: 40%
  - GERD symptoms: 32%
  - Respiratory symptoms since birth: 25%
  - Recent fever: 23%
  - Seizures: 11%
  - Metabolic disease: 1.5%
  - Ingestion of toxins: 1.5%
  - UTI: 1.1%
  - Structural heart lesion: 1%
  - Induced or fabricated illness or child abuse
  - 2/3 present with one of the following in the first few weeks of life
    - Cyanotic episodes
    - Repeated apneas
    - Pallor



# Brief Resolved Unexplained Event (BRUE)

## Lower-Risk BRUE

- No concerns from history and exam
- Age >60 days
- Born  $\geq 32$  weeks + corrected  $\geq 45$  weeks
- No CPR by trained provider
- Event <1 minute in duration
- First event

Follow Lower-Risk  
BRUE Guideline  
Management  
Recommendations

## Higher-Risk BRUE

- Any concerns on history and exam
- Age  $\leq 60$  days
- Born <32 weeks + corrected  $\leq 45$  weeks
- CPR done by trained provider
- Event  $\geq 1$  minute in duration
- Second, cluster, or recurrent events

Out of BRUE  
Guideline Scope;  
Manage  
Correspondingly



**BRUE** describes an event that:

- Occurs in a **child younger than 1 year of age**,
- **Lasts less than 1 minute** (typically 20-30 seconds),
- Has **one or more** of the following:
  - **Central Cyanosis** or **Pallor**
    - Discoloration of face, gums and/or trunk.
    - Not acrocyanosis or only peri-oral cyanosis
    - Not rubor / redness
  - **Absent, Decreased, or Irregular breathing**
    - Central or obstructive or mixed apnea
    - Not periodic breathing or **breath holding spell**.
  - Marked **change in tone** (hypertonia or hypotonia)
  - **Altered level of responsiveness**
- **Resolves and patient returns to baseline**, and
- Has a **reassuring history, physical exam, and vital signs** during ED evaluation.

**ALTE?**  
No Longer Speak  
of Such Things.  
  
Let's Enjoy This  
Tasty **BRUE**  
Instead.



## BRUE: Brief Resolved Unexplained Event

- Infant < 1 year of age
- Includes  $\geq 1$  of the following (**TRAC**):
  - **T**one: Marked hypo- or hypertonia
  - **R**espirations: Absent, decreased, or irregular
  - **A**ltered level of responsiveness
  - **C**olor: Cyanosis or pallor
- No explanation after a thorough, appropriate history and physical exam
- BRUE is previously known as **ALTE** (Apparent Life Threatening Event)

Mnemonic:  
BLUE **TRAC**TOR



@jackcfchong



# BRUE

## CHILD < 1 YR OLD

**Clinician** characterizes event as a sudden, brief, resolved episode of one or more of the following:

- Cyanosis or pallor
- Absent, decreased, or irregular breathing
- Marked change in tone
- Altered responsiveness

If event criteria present → Appropriate H&P

If NO explanation then you diagnose  
**Brief Resolved Unexplained Event**

### Low Risk

- Age >60 days
- Born ≥32 wks & corrected gestational age ≥45 wks
- No CPR by trained medical provider
- Event lasted <1 minute
- First event

### High Risk

Out of guideline scope.

Manage accordingly

### Should

- Educate caregivers about BRUEs & engage in shared decision making to guide eval, dispo and follow up.
- Offer CPR training resources

### May

- Obtain pertussis testing and/or 12-lead ECG
- Briefly monitor patient with pulse ox and serial observations

### Should not

- Obtain labs or other studies.
- Initiate home cardio-respiratory monitoring
- Prescribe antacids or anti epileptic medications

### Need Not

- Obtain respiratory test, UA, glucose, serum NaHCO<sub>3</sub> or Lactic acid, labs for anemia or neuroimaging.
- Admit the patient solely for cardiorespiratory monitoring.



# BRUE VS SIDS

- Link between them is weak
- Different disease process
- The only prominent risk factors for both is maternal smoking during pregnancy



**FOUNDATIONS CHALLENGE**  
**CLINICAL CONCEPTS**

**NAME 2 RISK FACTORS FOR SUDDEN  
UNEXPLAINED DEATH IN INFANCY (SUDI).**



**FOUNDATIONS CHALLENGE**  
**CLINICAL CONCEPTS**

**NAME 2 RISK FACTORS FOR SUDDEN  
UNEXPLAINED DEATH IN INFANCY (SUDI).**

**Age <2**

**Soft sleep surface**

**Maternal smoking/drugs**

**Male infant**

**Prone sleeping**

**Prematurity**





# SUDDEN INFANT DEATH SYNDROME (SIDS)

SIDS is the sudden death of an infant during the first year of life from an illness of unknown etiology.



# APNEA

- No respiration for  $> 20$  seconds
- ALTE (acute life-threatening event) / SIDS
- Now called ... BRUE (brief resolved unexplained events)
  - Apnea, color change, choking, gagging, change in muscle tone
  - 2-3 months old
  - Requires admission, septic work up, X-rays, head CT
  - Differential diagnosis:
    - Sepsis, hypoglycemia, seizures, GER, anemia, abuse, metabolic disturbances



# SIDS

- Most common cause of death of infants between 1 mo to 1 y/o
- Risk factors:
  - Prematurity with low birth weight
  - Previous episode of ALTE/BRUE
  - Mother is a substance abuser
  - Sibling of infant who died of SIDS



# SHOCK AND ALOC IN THE NEWBORN (THE MISFITS)

- Trauma / NAT (non-accidental trauma)
- Heart disease – congenital / hypovolemia / hypoxia
- Electrolyte disturbances
- Metabolic disturbances (congenital adrenal hyperplasia)
- Inborn errors of metabolism
- Sepsis
- Formula dilution or over concentration
- Intestinal catastrophe
- Toxins (home remedies, honey, Reye's syndrome)
- Seizures / CNS abnormalities



- A 3-month-old infant presents with poor feeding and hypotonia. What is the most appropriate first step?
- a. Blood culture
- b. CT of head
- c. LP
- d. Bedside blood glucose



A one-week-old presents with probable meningitis. The best regimen is:

- a. Ampicillin and cefotaxime
- b. Ampicillin and ceftriaxone
- c. Gentamicin
- d. Cefotaxime
- e. Ampicillin



What is the most common organism for meningitis in an 8 months old child?

- a. Listeria, S. pneumoniae, H. influenzae*
- b. E. coli, Group B Streptococcus, N. meningitidis*
- c. S. pneumoniae, H. influenzae, N. meningitidis*
- d. Listeria, E. coli, S. pneumoniae*



# PEDIATRIC FEVER (without source)

0 – 28 days Septic Workup and Admit	
CBC	Cefotaxime 50 mg/kg
Blood culture	Ampicillin 100 mg/kg
UA	(Amp + Genta)
Urine culture	(Chloramphenicol if PCN Allergic)
CXR	Concerned about HSV:
Stool culture	HSV PCR
CSF studies: GS, C&S, protein, glucose, cell counts	Acyclovir 20 mg/kg

29 days – 60 days	
<b>Option 1 (toxic or <math>\geq 101.3^\circ</math> F)</b>	<b>Option 2 (<math>\geq 100.4^\circ</math> F)</b>
0 – 28 days old pathway	CBC
	Blood culture
	UA and urine culture
	RSV / Influenza
	CXR
	If positive:
	Ceftriaxone 50 mg/kg
	Admit
	If negative:
	Antipyretics
	24 hr follow up

61 days – 90 days	
<b>Option 1 (toxic)</b>	<b>Option 2 (<math>\geq 102.2^\circ</math> F)</b>
0 – 28 days old pathway	CBC
	Blood culture
	UA and urine culture
	RSV / Influenza
	CXR
	Consider LP
	If positive:
	Ceftriaxone 50 mg/kg
	Admit
	If negative:
	Antipyretics
	24 hr follow up

3 months – 36 months	
<b>Option 1 (toxic)</b>	
0 – 28 days old pathway	
<b>Option 2 (<math>\geq 102.2^\circ</math> F)</b>	
UTI Risk Factors	
Male < 24 months	Female
<ul style="list-style-type: none"> <li>Fever &gt; 102.2° F</li> <li>Fever &gt; 48 hrs</li> <li>Non-black race</li> <li>No other source</li> </ul>	<ul style="list-style-type: none"> <li>Fever &gt; 102.2° F</li> <li>Fever &gt; 48 hrs</li> <li>White</li> <li>No other source</li> <li>&lt; 12 months</li> </ul>
Consider UA and culture if:	
<ul style="list-style-type: none"> <li>Uncircumcised male with any risk factors</li> <li>Female with <math>\geq 2</math> risk factors</li> <li>Circumcised male with <math>\geq 3</math> risk factors</li> </ul>	
Treat with empiric oral antibiotic and 24 hours follow up	
Bacteremia Risk Factors with < 2 PCV/Hib vaccinations	
<ul style="list-style-type: none"> <li>Fever &gt; 103° F</li> <li>Petechial rash</li> <li>+ UTI and/or diarrhea</li> </ul>	
If any Risk Factors present, consider:	
<ul style="list-style-type: none"> <li>Blood culture</li> <li>CBC</li> <li>CRP and/or PCT</li> </ul>	
Treat with ceftriaxone 50 mg/kg and 24 hours follow up	
Pneumonia Risk Factors	
Acute Pneumonia	Occult Pneumonia
<ul style="list-style-type: none"> <li>&lt; 2 PCV/Hib vaccinations</li> <li>Fever and cough</li> <li>Focal lung findings</li> <li>Retractions</li> <li>O2 Sat &lt; 92%</li> <li>Less likely if wheezing</li> </ul>	<ul style="list-style-type: none"> <li>Fever &gt; 102.2° F for &gt; 5 days</li> <li>Cough</li> <li>WBC 20,000</li> </ul>
If risk factors and clinical concern warrant, consider CXR	
<ul style="list-style-type: none"> <li>Treat with ceftriaxone 50 mg/kg, amoxicillin 80-90 mg/kg and closed follow up</li> </ul>	





# SEPSIS

- Most common organisms causing bacteremia
  - *S. pneumoniae* and *H. influenzae*
- Most common organisms causing sepsis in the neonates
  - *Group B streptococcus* and *E. coli*
- Most common organisms causing sepsis after the newborn period
  - *N. meningitidis*, *S. pneumoniae* and *H. influenzae*



# MENINGITIS

- Most common organisms in neonates
  - *Group B streptococcus, Listeria, and E. coli*
- Most common organisms in 3 months/old to 3 y/o
  - *N. meningitidis, S. pneumoniae and H. influenzae*
- Most common organisms in > 3y/o
  - *S. pneumoniae and H. influenzae*



**FOUNDATIONS CHALLENGE**  
**RAPID FIRE**

**Infant + Poor Feeding + Recurrent PNA**

**Diagnosis???**

**Croup ssx → Toxic**

**Diagnosis???**

**Peds Trauma + Hypotension**

**Initial Bolus of Blood???**



**FOUNDATIONS CHALLENGE**  
**RAPID FIRE**

**Infant + Poor Feeding + Recurrent PNA**

**Tracheoesophageal Fistula**

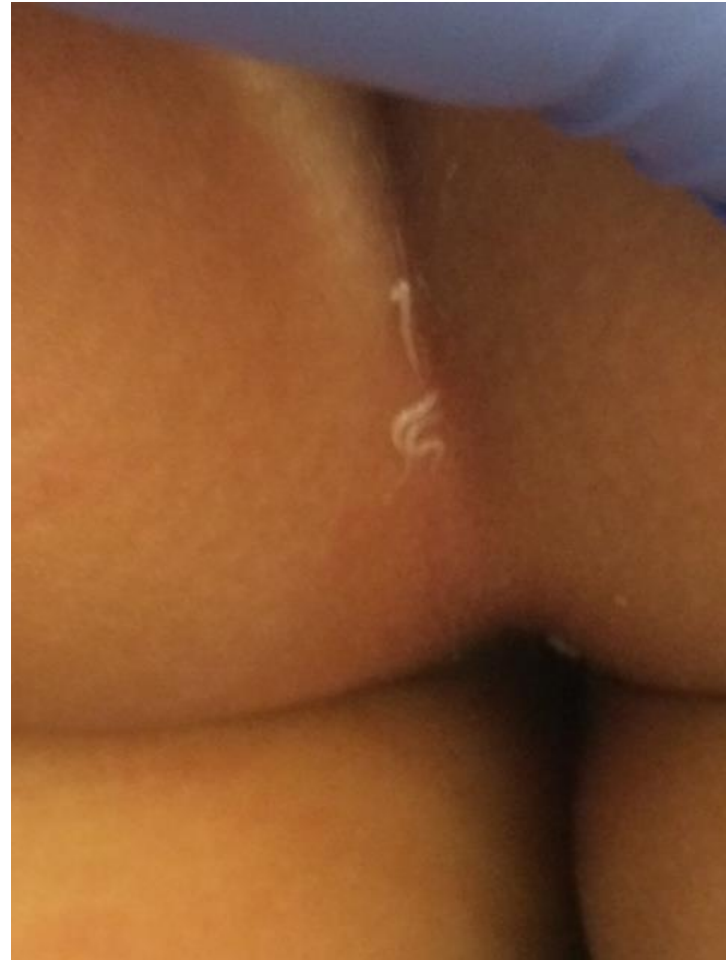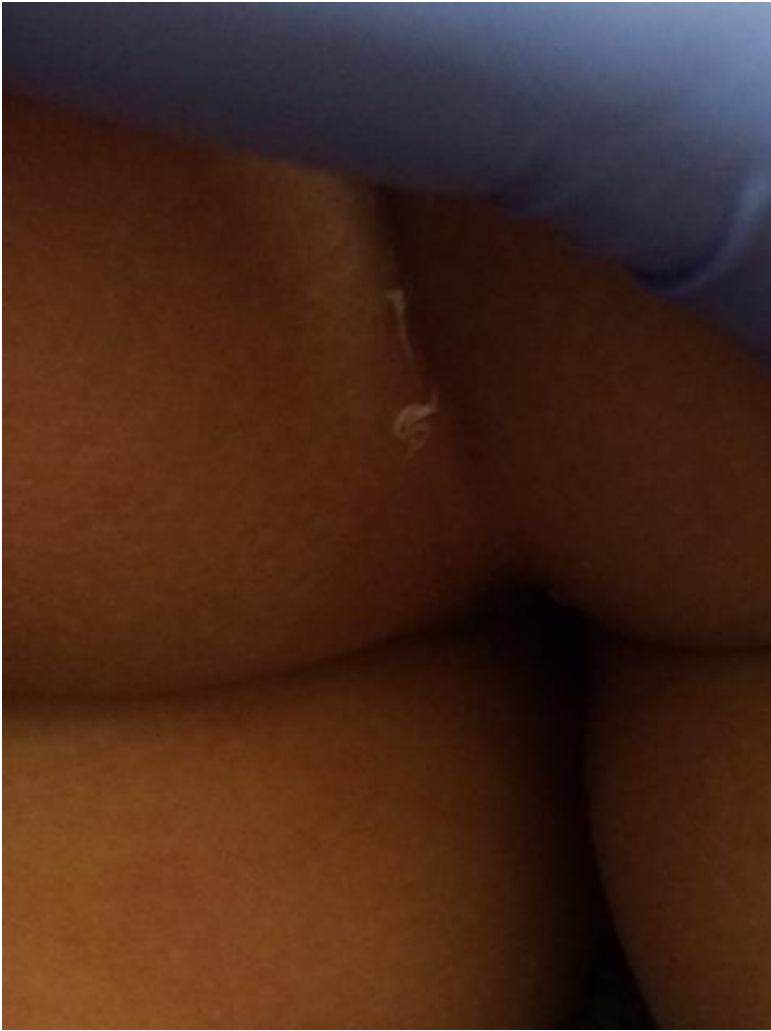**Croup ssx → Toxic**

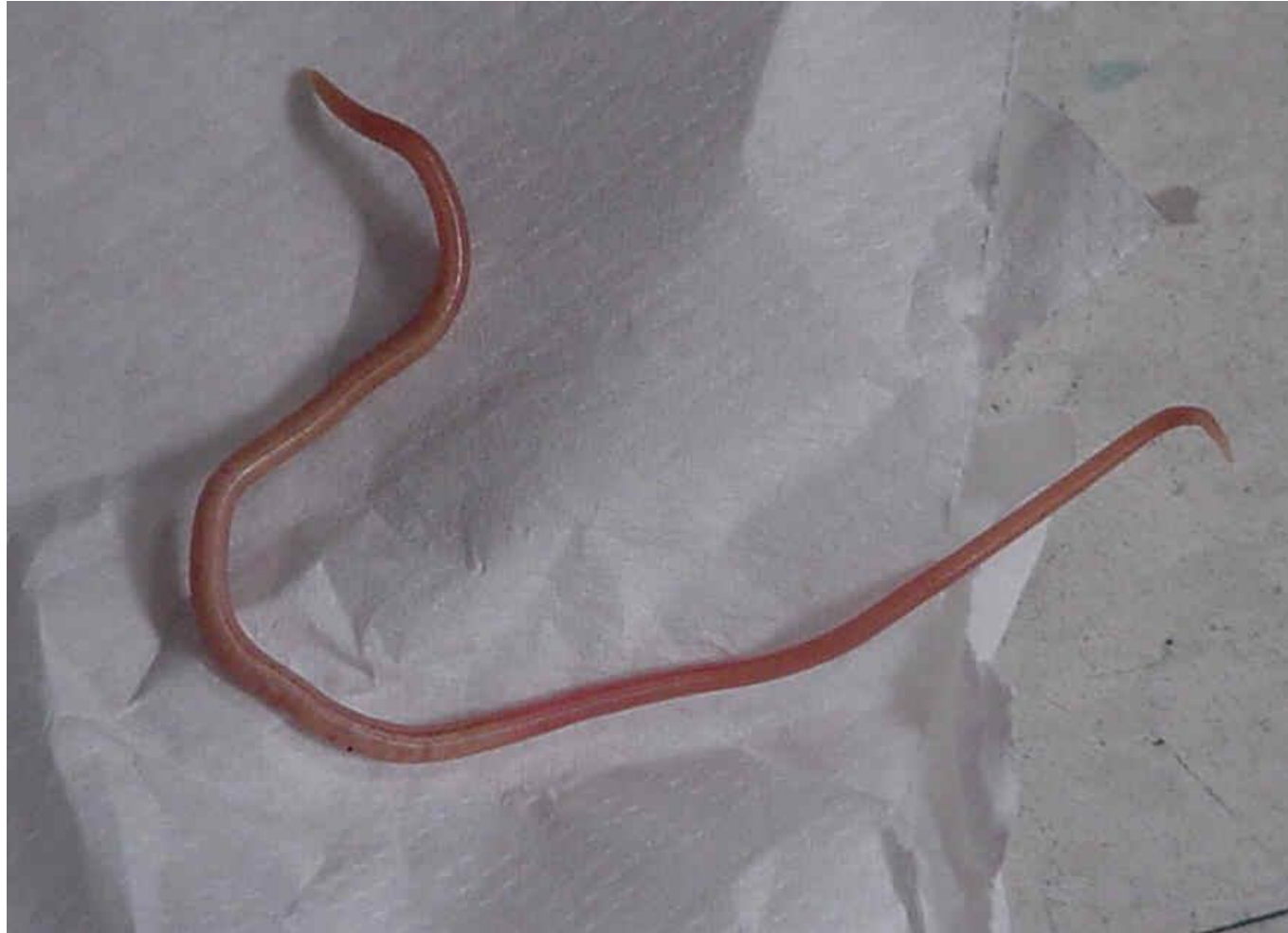**Bacterial Tracheitis**

**Peds Trauma + Hypotension**

**Blood: 10cc/kg**







**FOUNDATIONS CHALLENGE**  
**RAPID FIRE**

**Intermittent Abd Pain + Lethargy**

**Diagnosis???**

**Complication of Kawasaki**

**???**

**Neonate + Low Glucose**

**What do you give???**



**FOUNDATIONS CHALLENGE**  
**RAPID FIRE**

**Intermittent Abd Pain + Lethargy**

**Intussusception**

**Complication of Kawasaki**

**Coronary Artery Aneurysm**


**Neonate + Low Glucose**

**5mL/kg of D10**





# HOW TO CALCULATE PEDIATRIC MEDICATIONS

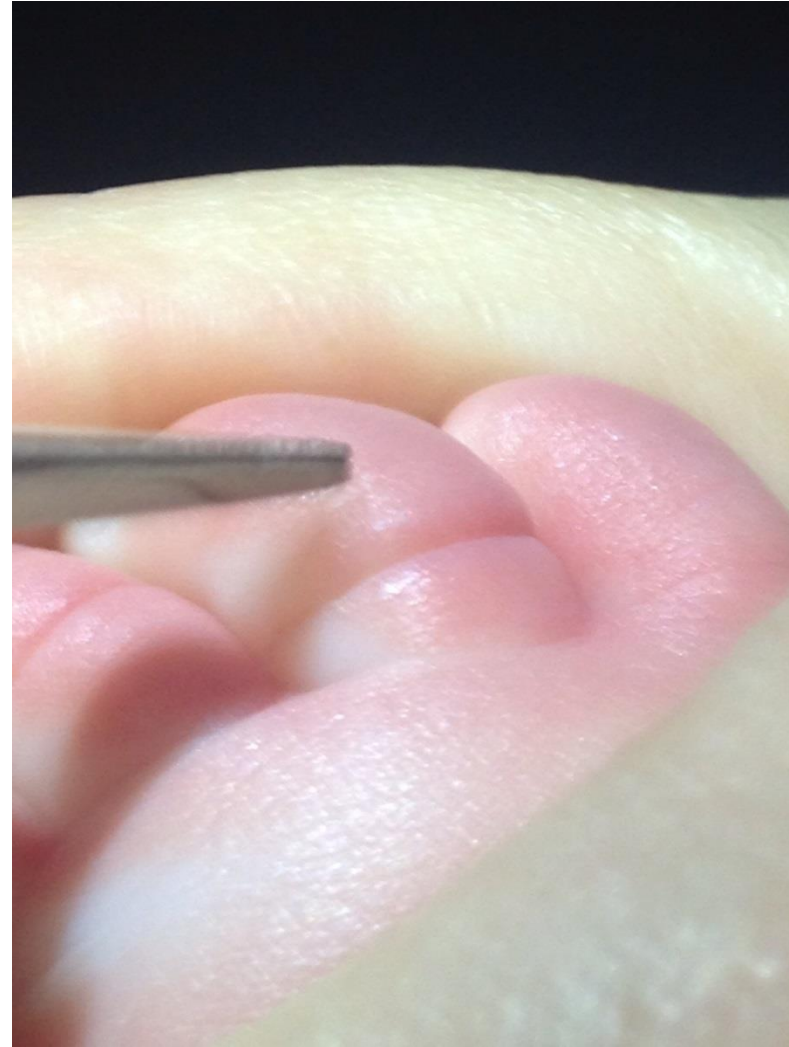
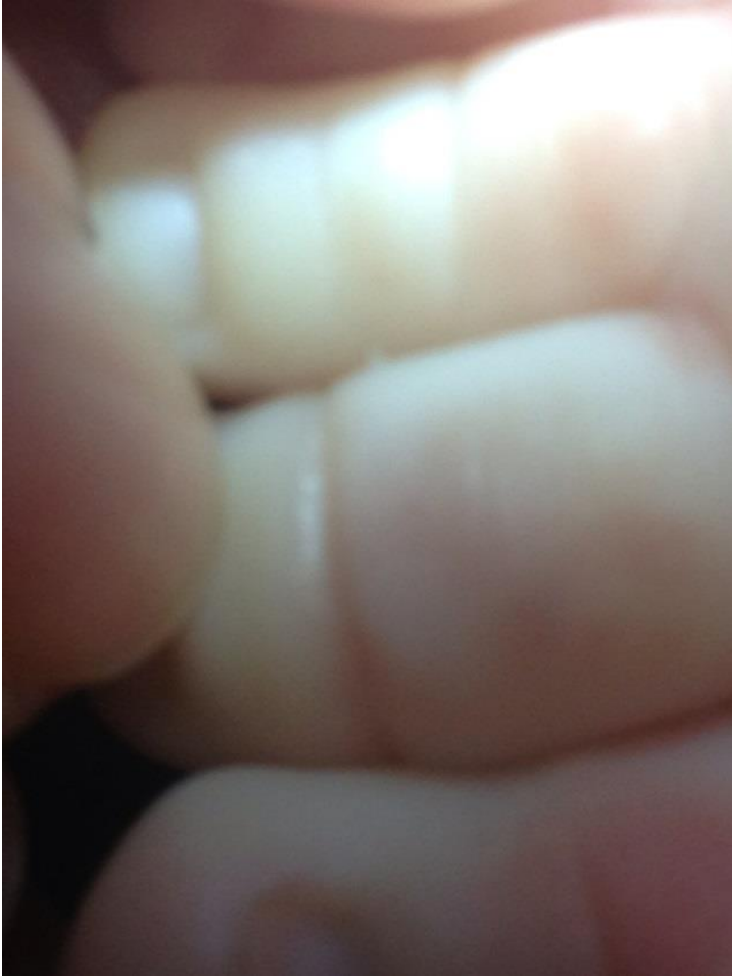

# BROSELOW TAPE



- **Baby crying inconsolable**
- **VSS**
- **Unable to find a cause for the baby's cry**





**FOUNDATIONS CHALLENGE**  
**RAPID FIRE**

**2yo + Recurrent RML PNA**

**Diagnosis???**

**5yo + Failed Airway**

**What to do???**

**Antalgic gait s/p Viral Illness**

**Diagnosis???**



**FOUNDATIONS CHALLENGE**  
**RAPID FIRE**

**2yo + Recurrent RML PNA**

**Aspirated Foreign Body**

**5yo + Failed Airway**

**Needle Cric**

**Antalgic gait s/p Viral Illness**

**Toxic Synovitis**



**FOUNDATIONS CHALLENGE**  
**RAPID FIRE**

When do you start chest compressions in a young child?

???

Joules to defibrillate children?

???

Tet spell initial management?

???



**FOUNDATIONS CHALLENGE**  
**RAPID FIRE**

When do you start chest compressions in a young child?

**HR < 60 (or pulseless)**

Joules to defibrillate children?

**2J/kg**

Tet spell initial management?

**Knee-chest position**





**FOUNDATIONS CHALLENGE**  
**RAPID FIRE**

Hypoglycemia in neonate?

Tx???

Hypoglycemia in 5-year-old?

Tx???

Painless abdominal mass, age 3-5?

Dx???



**FOUNDATIONS CHALLENGE**  
**RAPID FIRE**

**Hypoglycemia in neonate?**

**D10 at 5 cc/kg**

**Hypoglycemia in 5-year-old?**

**D25 at 2 cc/kg**

**Painless abdominal mass, age 3-5?**

**Wilms Tumor**



**FOUNDATIONS CHALLENGE**  
**RAPID FIRE**

**Painless rectal bleeding < 5yr**

**Diagnosis???**

**Bilious emesis <1yr**

**Diagnosis???**

**Premature + Gas in bowel wall**

**Diagnosis???**



**FOUNDATIONS CHALLENGE**  
**RAPID FIRE**

**Painless rectal bleeding < 5yr**

**Meckel's diverticulum**

**Bilious emesis <1yr**

**Midgut Volvulus**

**Premature + Gas in bowel wall**

**Necrotizing Enterocolitis**



**FOUNDATIONS CHALLENGE**  
**RAPID FIRE**

**Poor Family + Infant with Seizure**

**Cause???**

**Grandma's House + AMS + Pinpoint Pupils**

**Toxic Ingestion???**

**Boyfriend Babysits + Crying**

**Diagnosis???**



**FOUNDATIONS CHALLENGE**  
**RAPID FIRE**

**Poor Family + Infant with Seizure**

**Hyponatremia from Diluted Formula**

**Grandma's House + AMS + Pinpoint Pupils**

**Clonidine**

**Boyfriend Babysits + Crying**

**Trauma / Abuse**



- Compared to adults, infants and young kids have small airways
- Can quickly develop clinically significant upper airway obstruction
- Acute upper airway obstruction- whatever the etiology- can be life threatening
- Complete obstruction will lead to **respiratory failure** and **progress to cardiac arrest in minutes**
- Prompt recognition and management of airway compromise is critical to good outcome



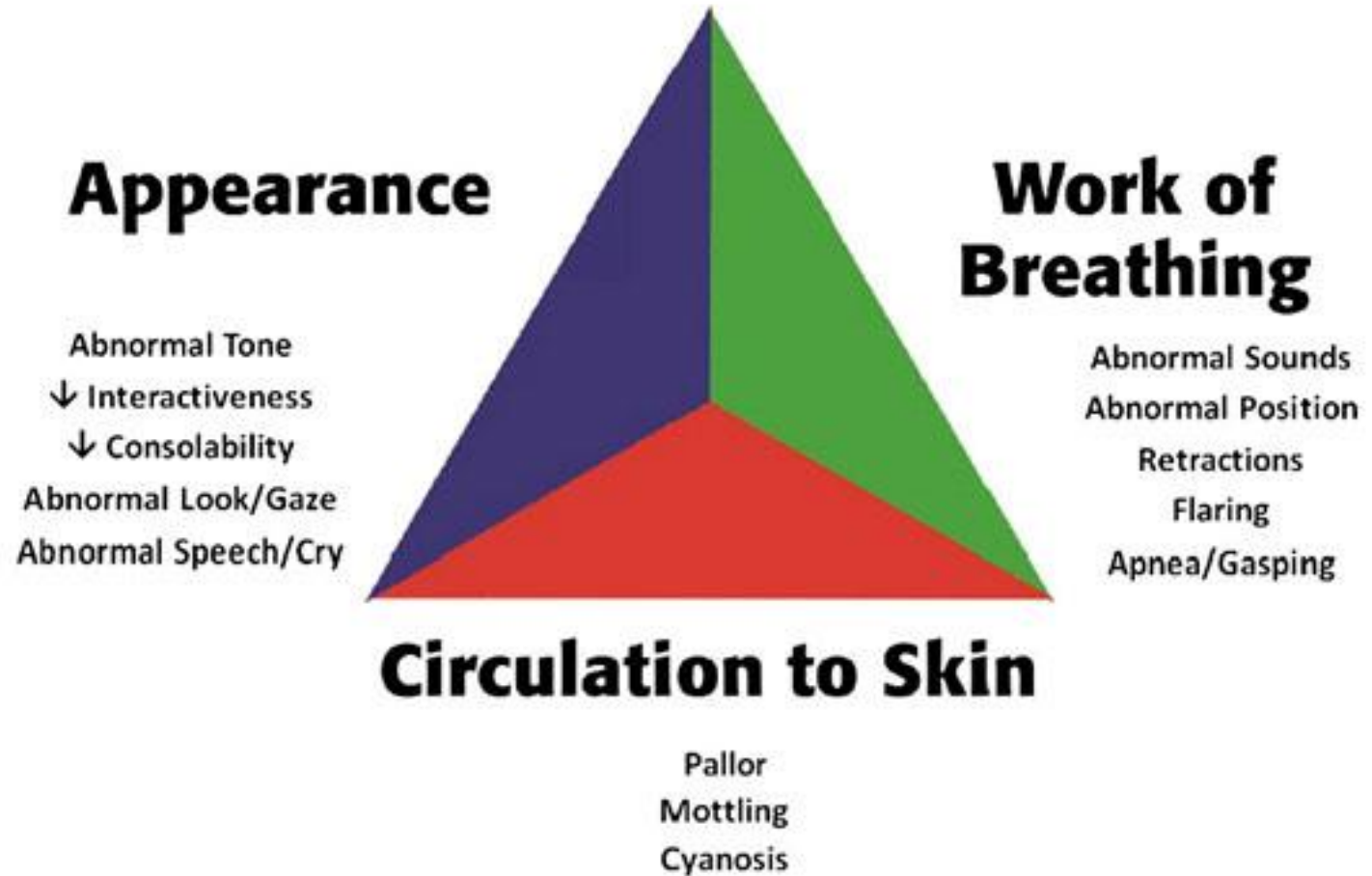
# PATHOPHYSIOLOGY

- Small caliber of airway makes it vulnerable for occlusion
- Exponential rise in airway resistance and WOB with any process that narrows airway
- Infant is nasal breather
  - Any obstruction of nasopharynx significantly increases WOB
- Large tongue can occlude airway especially increased ICP
  - Loss muscle tone due to decreased GCS
- Cricoid ring is narrowest part upper airway- often site occlusion in FB



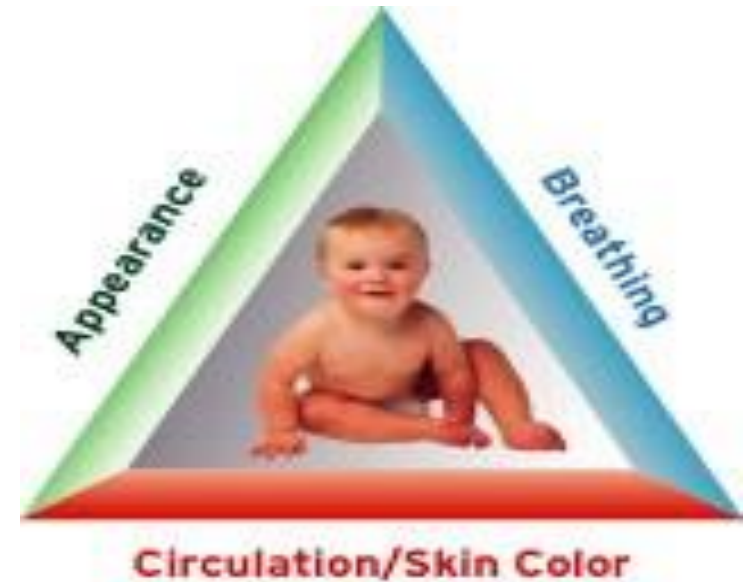

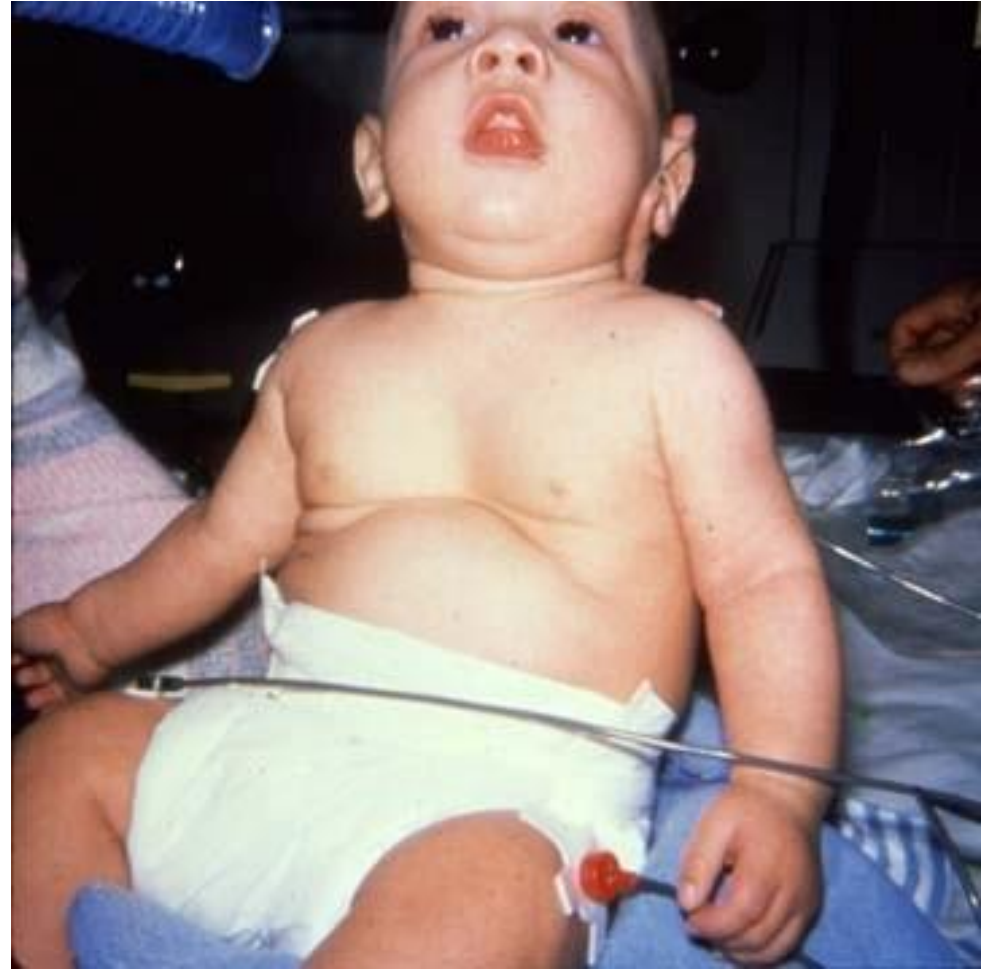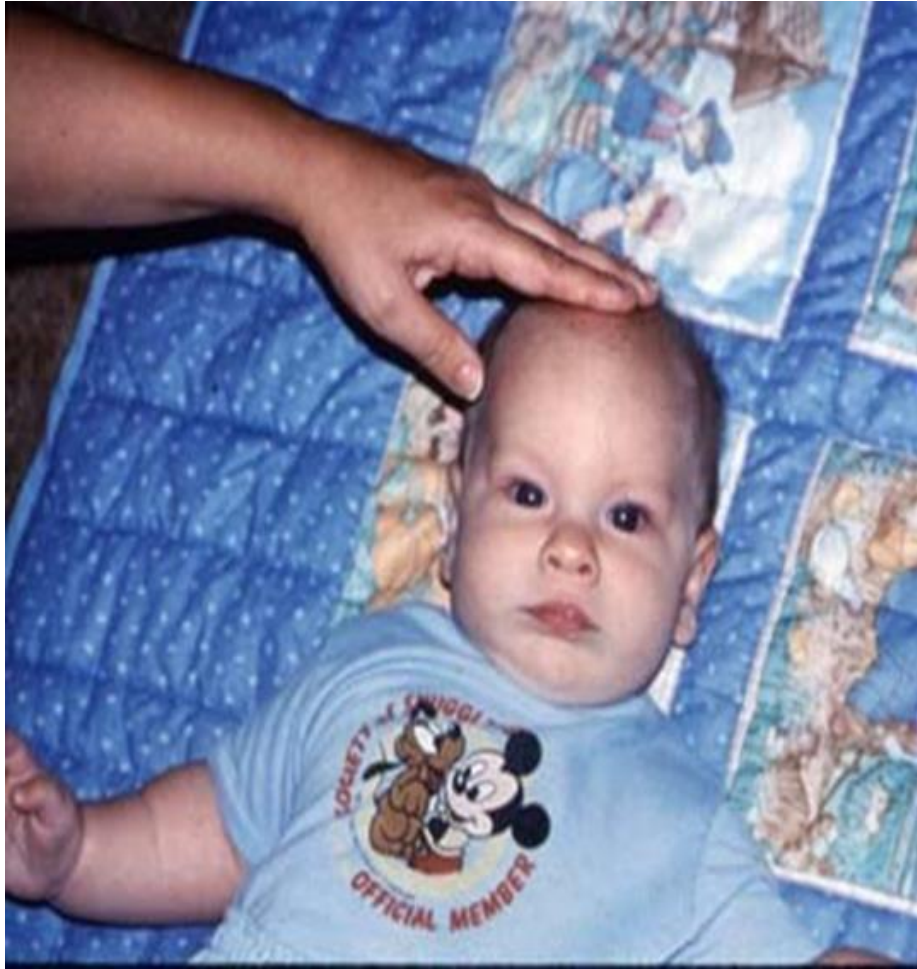# PEDIATRIC TRIANGLE ASSESSMENT



# Appearance

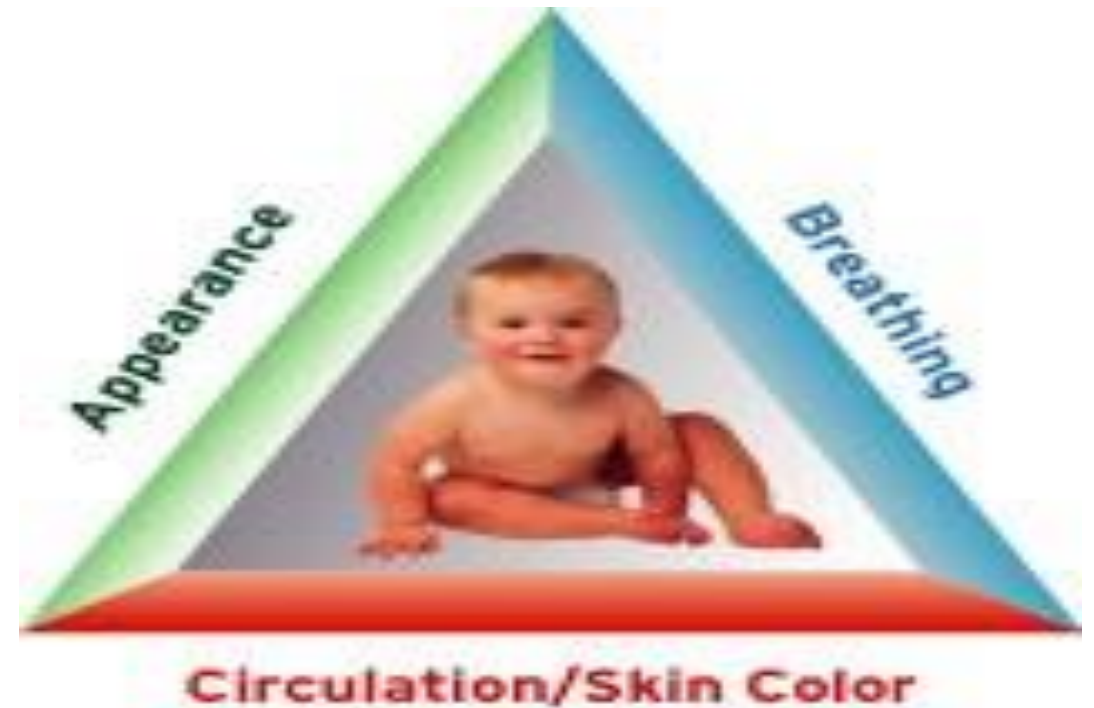- Level of consciousness
  - Irritability
  - Consolability
  - Distractibility
  - Eye contact
  - Agitation
  - Lethargy
  - Quality of Cry
  - Speech





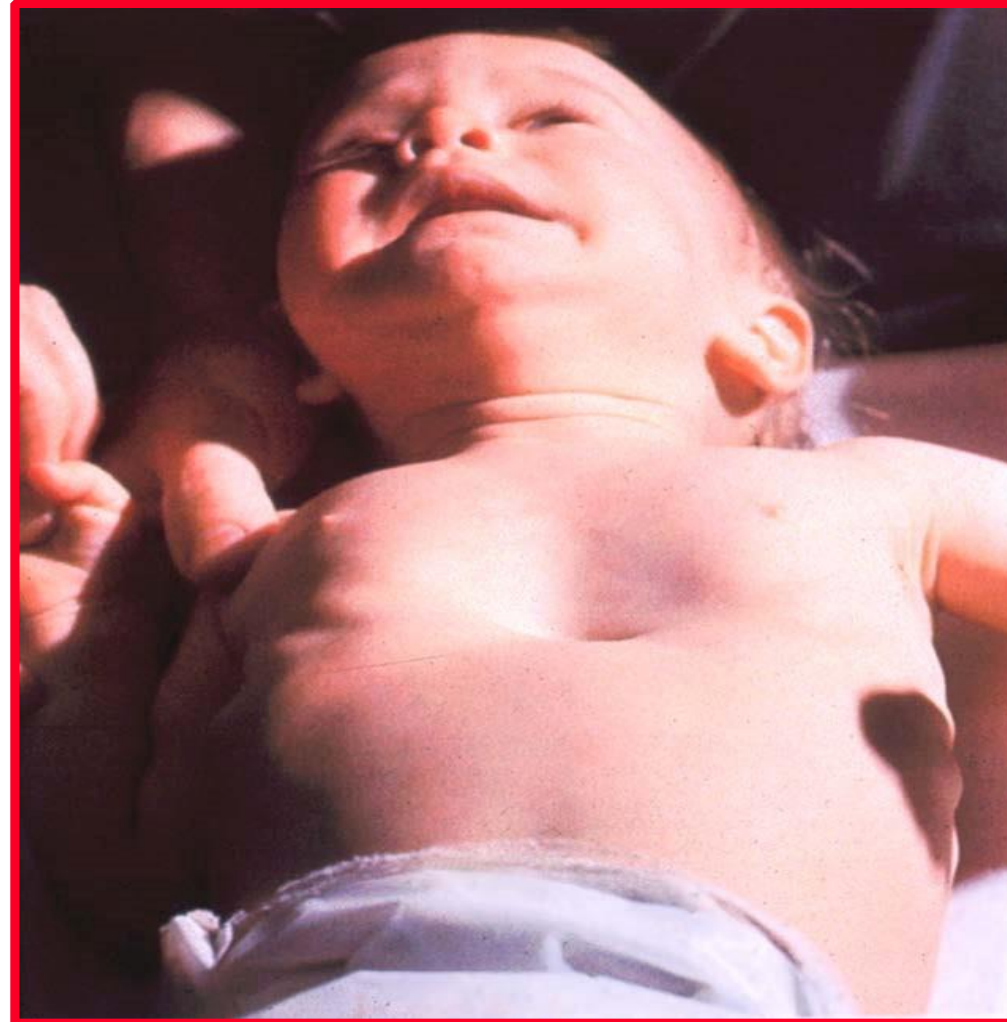# Breathing

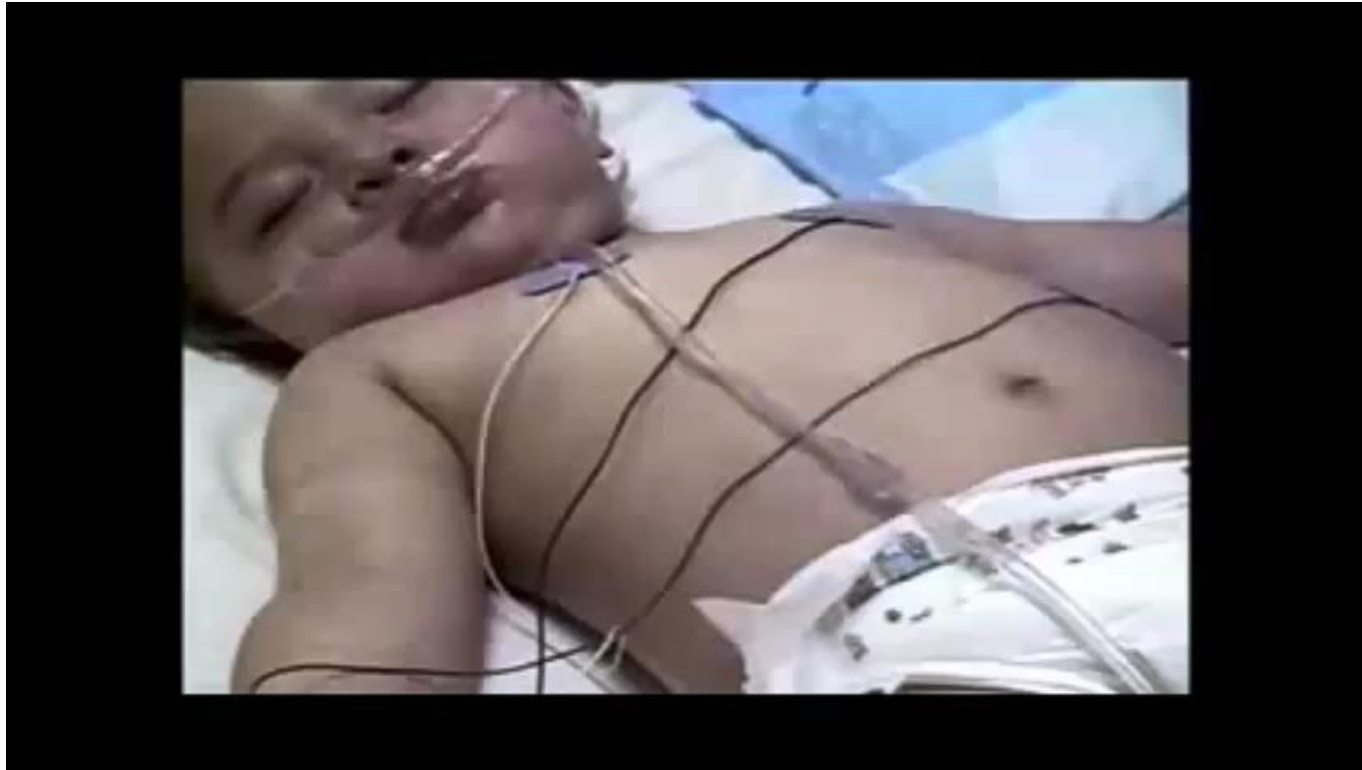- Tachypnea
- Work of breathing
- Abnormal sounds
- Position of comfort

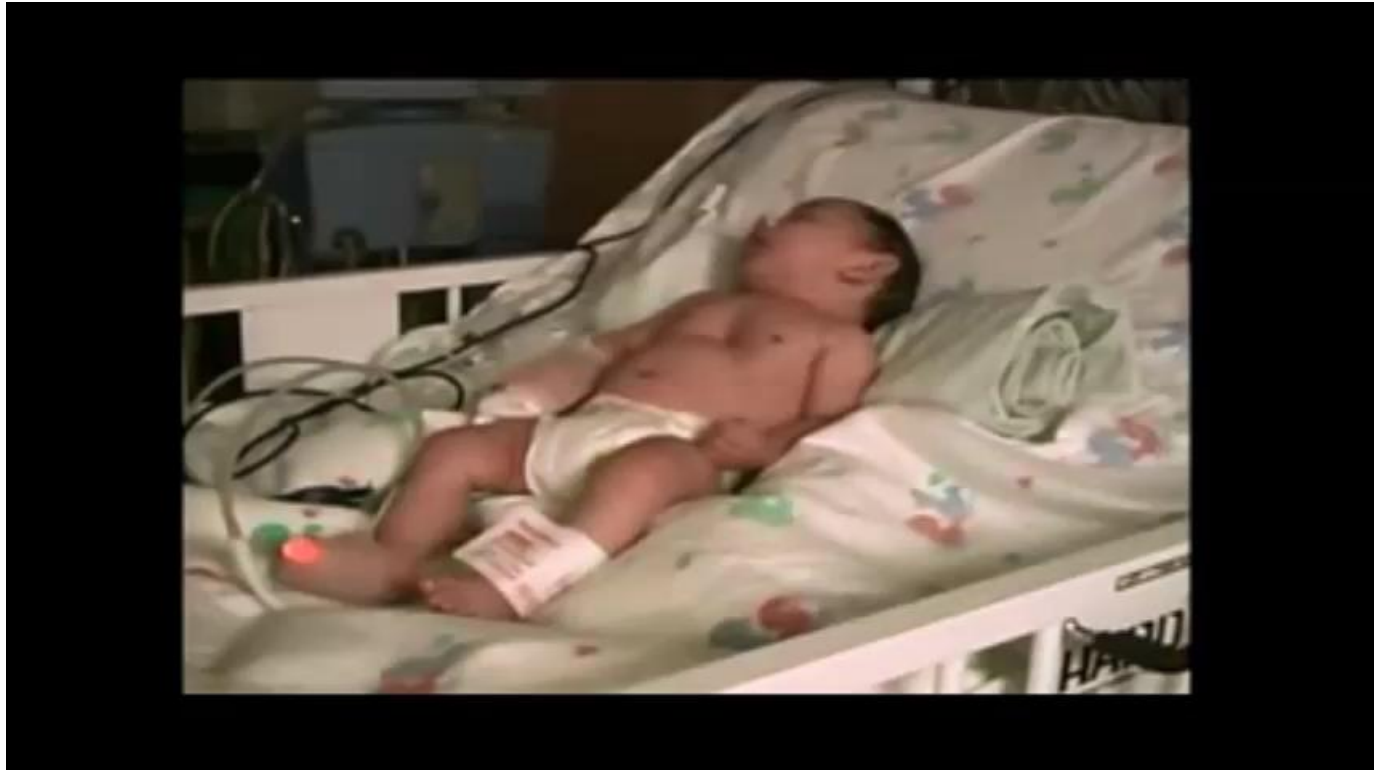

# Retractions

- Suprasternal
- Supraclavicular
- Intercostal
- Subcostal
- Nasal flaring







# Abnormal Sounds

- Grunting
  - Noted at end expiration
  - Voluntary closure of glottis
  - Physiologically generates PEEP
  - Worrisome sign
- Stridor
- Audible wheezing
- Crackles and rales





# STRIDOR

- Musical , high pitched inspiratory sound
- Hallmark of partial airway obstruction
- Pattern can localize the lesion
- **Supraglottic disease = inspiratory stridor**
  - Lesion at or above the cords
  - Inspiration: loose tissues collapse inward
  - Expiration: airway enlarges, tissues move
- **Subglottic disease = biphasic stridor**
  - lesion at or below vocal cords
  - Inspiration: loose tissues move inward
  - Expiration : fixed lumen size impedes air flow



# STRIDOR

- **Age of pt important**
  - Infants- congenital problems
  - Toddlers- foreign body
  - Older child = bigger airway → complete obstruction less likely
- Fever implies infectious etiology
- **Sudden onset** suggests :
  - Some infections
  - Foreign body
  - Anaphylaxis/ allergic rxn
- **Other non infectious causes:**
  - Anaphylaxis
  - Trauma/ caustic ingestion
  - Burn/ thermal injury



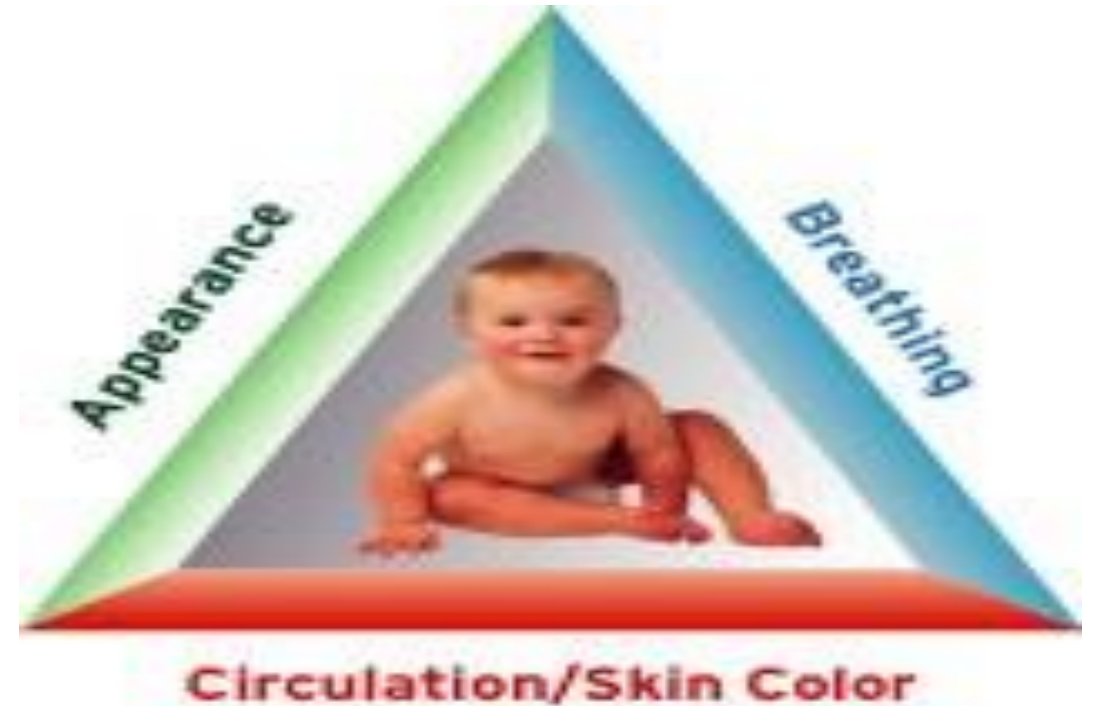# POSITION OF COMFORT

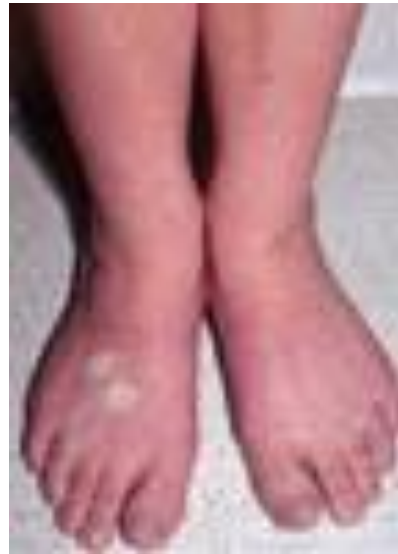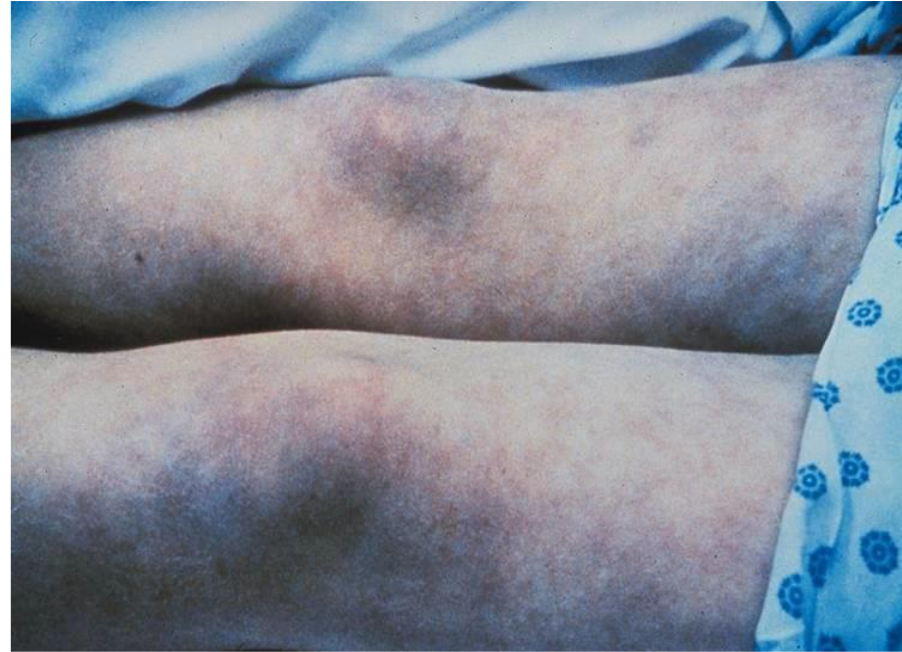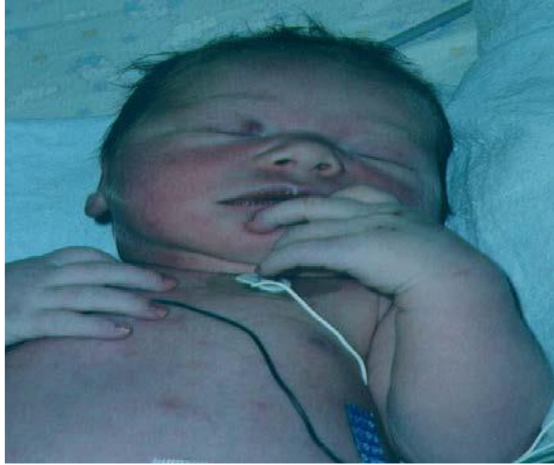- **Upper airway disease**
  - Upright posture, leaning forward
  - Self-generation of jaw thrust and chin lift
  - **“Sniffing” position**
- **Lower airway disease**
  - Upright posture
  - Leaning forward and support of upper thorax by arms
  - **Tripoding**



# CIRCULATION

- Capillary refill
- Distal vs central pulses
- Temperature of extremities
- Color
  - Pink
  - Pale
  - Blue (central cyanosis vs acrocyanosis)
  - Mottled





# RESPIRATORY EMERGENCIES

- Upper Airway
  - Stridor
  - Barking cough
  - Hoarseness
- Lower Airway
  - Wheezing
  - Prolonged expiratory phase
- Lung Tissue Disease
  - Grunting
  - Crackles
  - Decreased breath sounds
- Disordered Control of Breathing
  - Normal



# RESPIRATORY EMERGENCIES

- Upper Airway
  - Croup
  - Anaphylaxis
  - FB
- Lower Airway
  - Bronchiolitis
  - Asthma
- Lung Tissue Disease
  - Pneumonia / Pneumonitis (infective, chemical, aspiration)
  - Pulmonary edema (cardiogenic or non-cardiogenic)
- Disordered Control of Breathing
  - Increased ICP
  - Poisoning / Overdose
  - Neuromuscular Disease



# TYPICAL CAUSES OF DISTRESS

- Upper airway
  - Croup
  - Retropharyngeal abscess
  - Epiglottitis
  - Foreign body aspiration
- Lower airway
  - Reactive airway disease / asthma
  - Bronchiolitis
  - Pneumonia
  - Pneumothorax





# RESPIRATORY DISTRESS VS. FAILURE

## Distress

- Increased work of breathing (ventilatory effort)
- Open and maintainable
- Tachypnea
- Increased effort
- Good air movement
- Tachycardia
- Pallor
- Anxiety, agitation

## Failure

- Clinical condition in which there is inadequate blood oxygenation and/or ventilation to meet the metabolic demands of body tissues
- Not maintainable
- Bradypnea to apnea
- Apnea
- Poor to absent air movement
- Bradycardia
- Cyanosis
- Lethargy to unresponsiveness



# RESPIRATORY DISTRESS VS. FAILURE

## Distress

- Asthma / reactive airway disease
- Aspiration
- FB
- Congenital heart disease
- Infection
- Medication or toxin exposure
- Trauma

## Failure

- Infection
- FB
- Asthma / reactive airway disease
- Smoke inhalation
- Submersion syndrome
- Pneumothorax/hemothorax
- Congenital abnormalities
- Neuromuscular disease
- Medication or toxin exposure
- Trauma
- CHF
- Metabolic disease with acidosis



# WHY ARE KIDS DIFFERENT?

- Obligate nose-breathers
- Tongue relatively larger
- Higher larynx (C3-C4 versus C6)
- Narrowing of airway causes exponential rise of airway resistance
- Less elasticity of alveoli
- Lower FRC
- Diaphragm
  - Flatter
  - Muscle fibers more vulnerable to fatigue
- Chest wall
  - More compliant
  - Ribs more horizontal



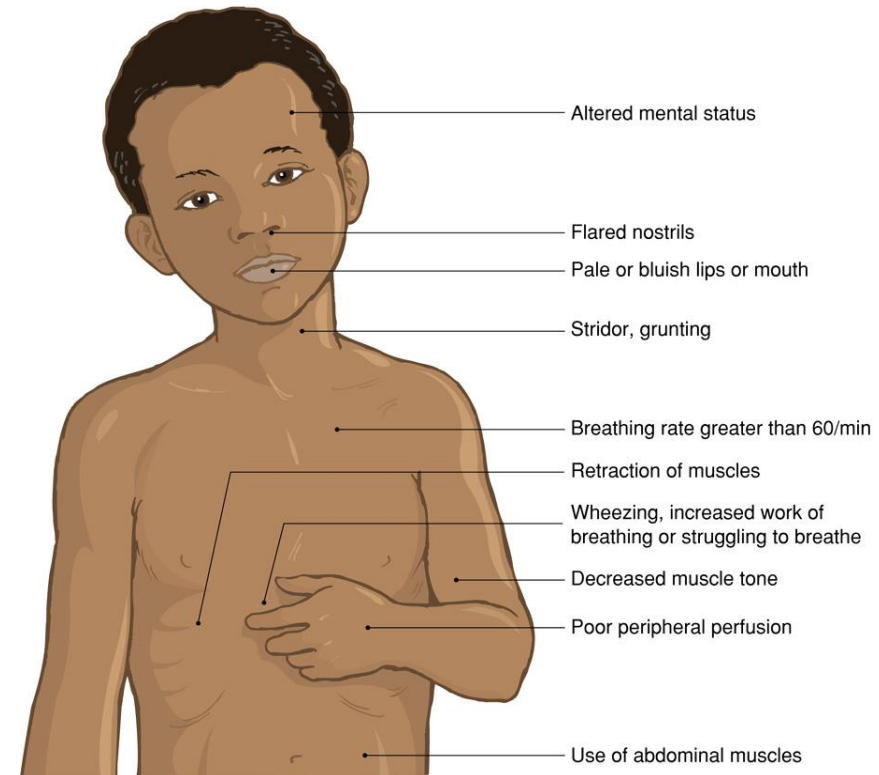
# SIGNS & SYMPTOMS OF DISTRESS

- Nasal flaring
- Hypoventilation, apnea
- Stridor
- Grunting
- Wheezing
- Pallor, ashen color
- ↑ WOB
- Tachypnea
- Cyanosis
- Head bobbing
- Tripod positioning
- Retractions
- ↓ Level of consciousness
- ↓ Air movement
- Acidosis
- Hypercapnea



# SIGNS OF RESPIRATORY DISTRESS

Notice the conditions that can be determined by quick observation



# SIGNS OF INCREASED RESPIRATORY EFFORT

Table 2-3

SIGNS OF INCREASED RESPIRATORY EFFORT

Retraction	Visible sinking of the skin and soft tissues of the chest around and below the ribs and above the collarbone
Nasal flaring	Widening of the nostrils; seen primarily on inspiration
Head bobbing	Observed when the head lifts and tilts back as the child inhales and then moves forward as the child exhales
Grunting	Sound heard when an infant attempts to keep the alveoli open by building back pressure during expiration
Wheezing	Passage of air over mucous secretions in bronchi; heard more commonly upon expiration; a low- or high-pitched sound
Gurgling	Coarse, abnormal bubbling sound heard in the airway during inspiration or expiration; may indicate an open chest wound
Stridor	Abnormal, musical, high-pitched sound, more commonly heard on inspiration



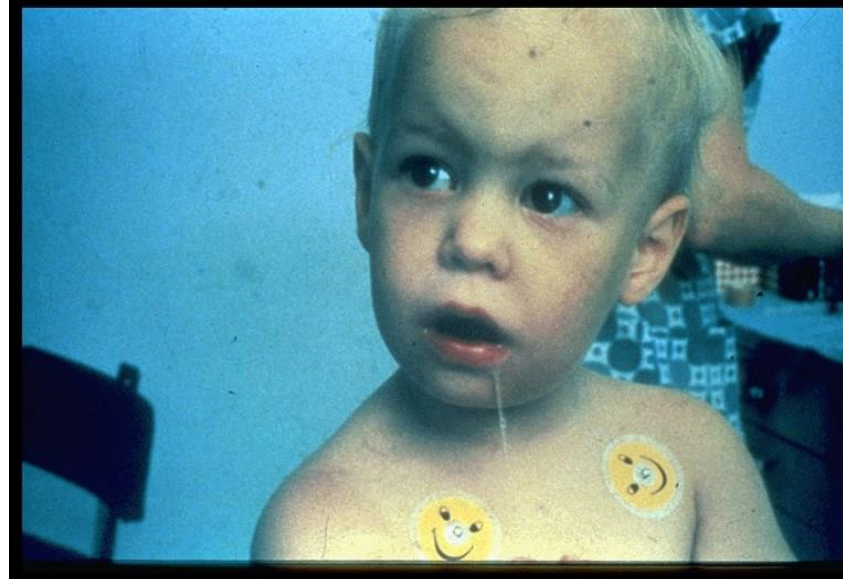
# ANTICIPATING CARDIOPULMONARY ARREST

- Respiratory rate greater than 60
- Heart rate greater than 180 or less than 80 (under 5 years)
- Heart rate greater than 180 or less than 60 (over 5 years)
- Respiratory distress
- Trauma
- Burns
- Cyanosis
- Altered level of consciousness
- Seizures
- Fever with petechiae



# Case 1

- 4-year-old boy in good health
- Sore throat, fever, no appetite
- Trouble swallowing, stridor
- Pulse 140, respirations 30 to 40
- Anxious, drooling
- How sick is this child?





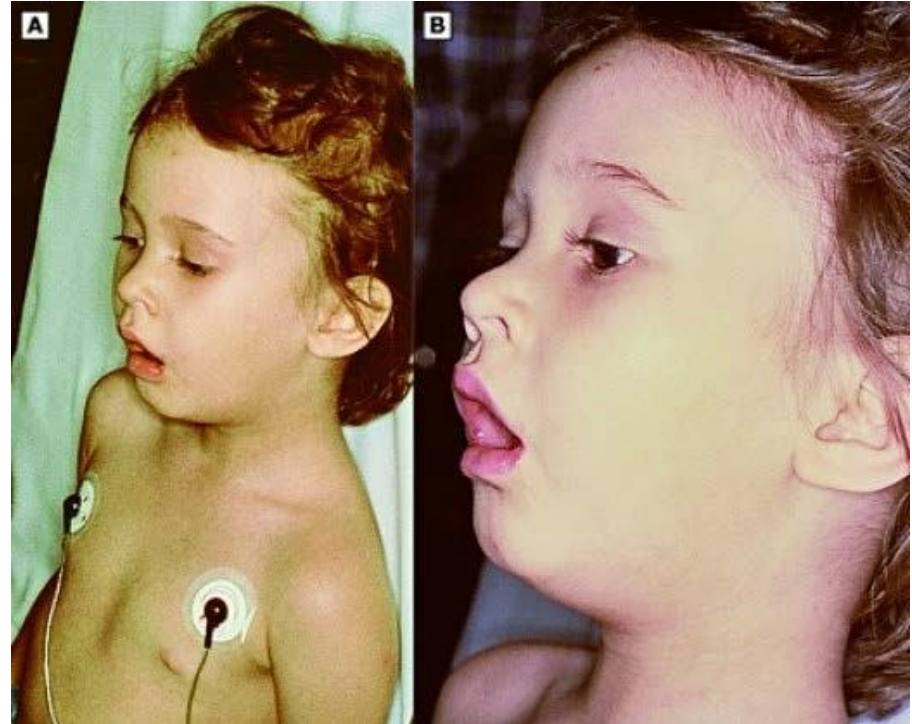# DIFFERENTIAL DIAGNOSES OF UPPER AIRWAY OBSTRUCTION

- Retropharyngeal abscess
- Peritonsillar abscess
- Croup
- Caustic ingestion
- Epiglottitis
- Foreign body obstruction
- Bacterial tracheitis



# Immediate Steps

- Reduce child's anxiety
- Provide supplemental oxygen
- Minimize procedures
- Avoid oral examination
- Prepare airway equipment
- Alert OR, anesthesiologist, surgeon
- Prepare to move to OR if needed



# EPIGLOTTITIS

- Acute, rapidly progressive cellulitis of the epiglottis and adjacent structures
- Before immunization - peak incidence at 3.5 years of age
- Danger of airway obstruction - medical emergency
- Prompt diagnosis and airway protection required



# EPIGLOTTITIS - SIGNS & SXS

- More acute presentation in young children than in adolescents or adults
- Symptoms for <24 hrs
  - High fever, severe sore throat, tachycardia, systemic toxicity, drooling, tripod position
- Moderate or severe respiratory distress with inspiratory stridor & retractions



## EPIGLOTTITIS

- A • Airway Inflammation → Obstruction
- I • Increased Pulse
- R • Restlessness

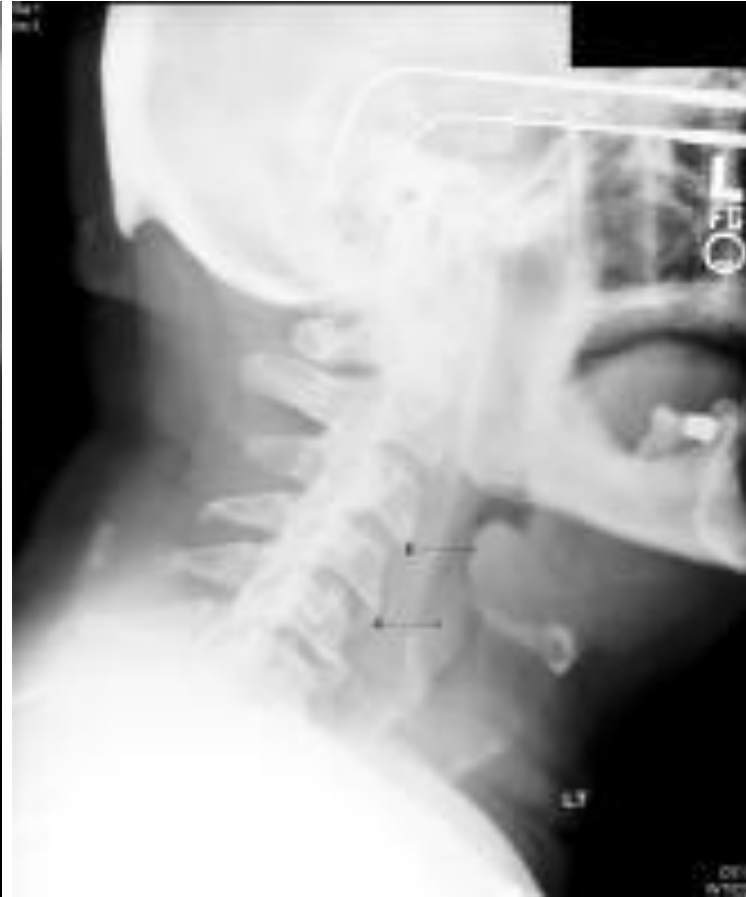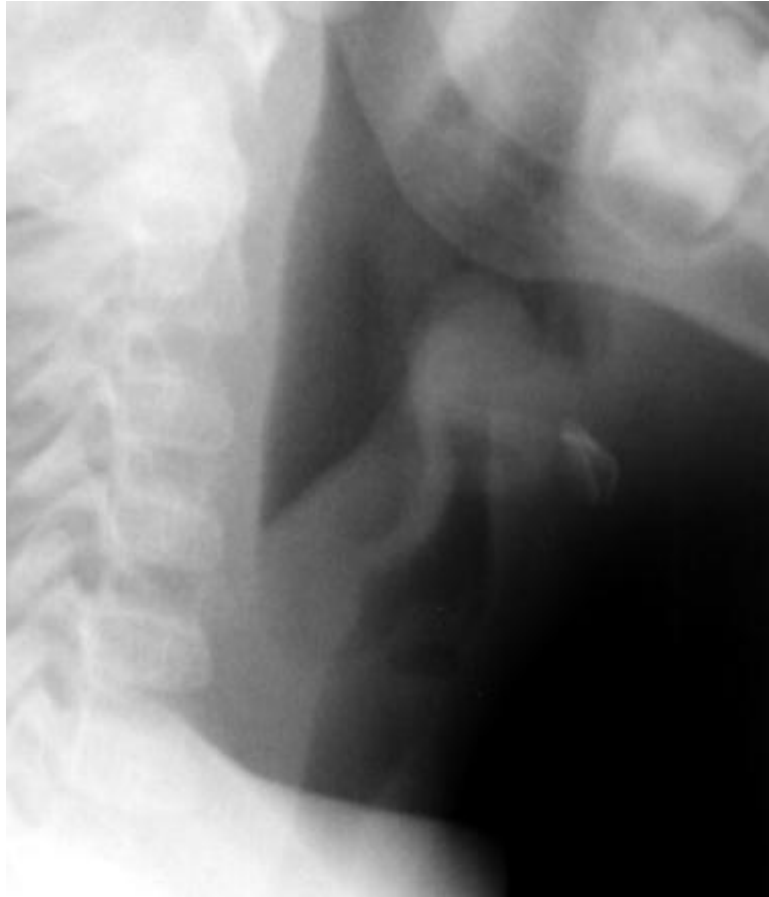- R • Retractions
- A • Anxiety Increased
- I • Inspiratory Stridor
- D • Drooling

### TREATMENT:

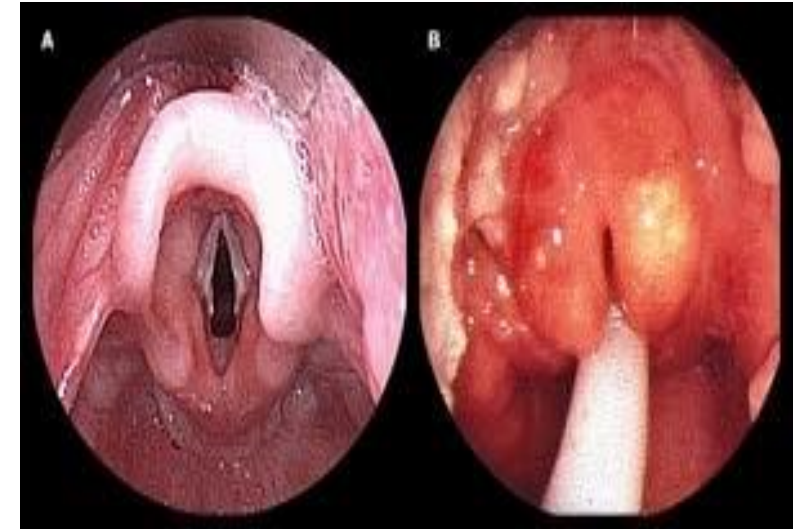
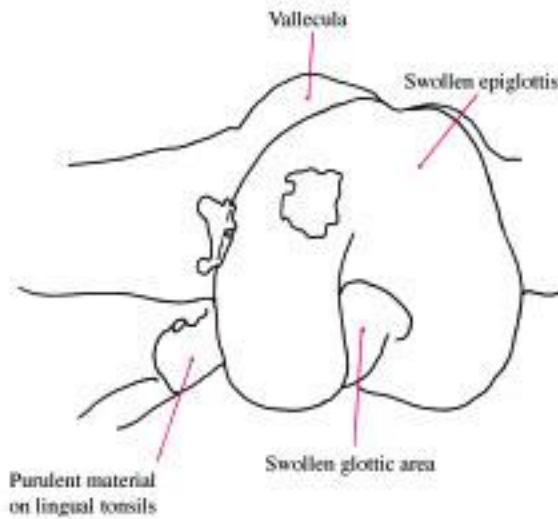
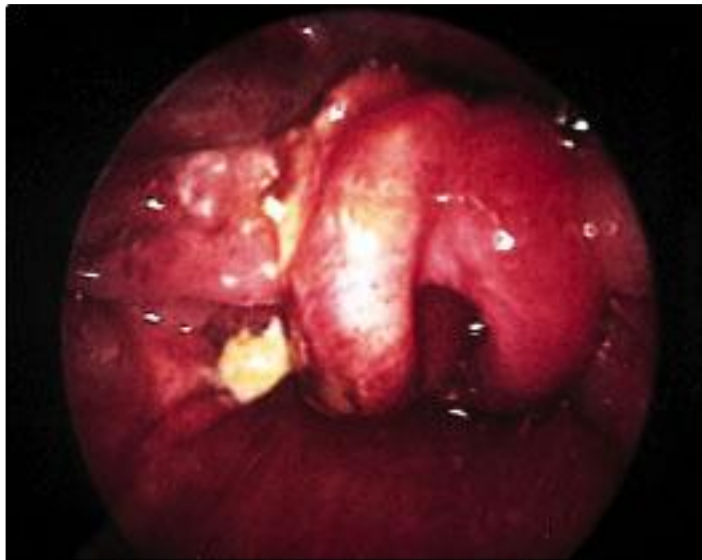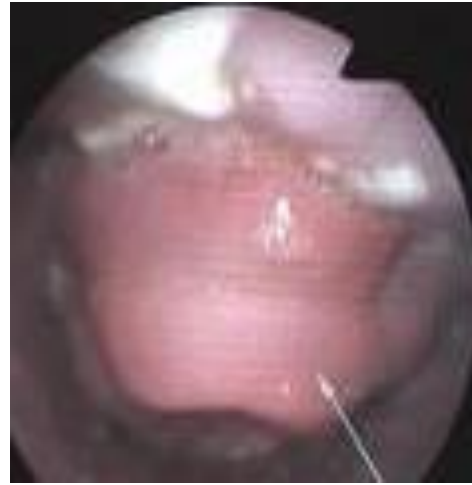
- ↓ Anxiety
- Don't Examine Throat
- ~~Tongue Blade~~
- Position For Comfort
- Trach Tray or Endotracheal Tube Available
- Cool Mist Humidification
- Oxygen
- No Oral Fluids
- IV Fluids



# EPIGLOTTITIS - LATERAL NECK FILM



# EPIGLOTTITIS



Copyright ©2006 by The McGraw-Hill Companies, Inc.  
All rights reserved.



# EPIGLOTTITIS - ETIOLOGY

- Group A Streptococcus
- Other pathogens seen less frequently include:
  - Strep pneumoniae
  - Haemophilus parainfluenza
  - Staph aureus



# EPIGLOTTITIS - RX & TRANSPORT

- Position of comfort, with parent
- Minimize manipulation
- Intubation under controlled circumstances
- O<sub>2</sub> prn, blow-by if not tolerating mask
- Avoid agitation (Do not try to start IV, obtain blood or examine airway!)
- Consult anesthesia & ENT
- IV for antibiotics, after airway secure





# EPIGLOTTITIS - TROUBLE

- If respiratory arrest →→ BVM ventilation →→ if inadequate, attempt to intubate →→ if unable to intubate, perform needle or surgical cricothyroidotomy
- IV antibiotics
  - ceftriaxone / cefotaxime
- Racemic epinephrine & steroids are **ineffective**



# RETROPHARYNGEAL ABSCESS

- Deep, potential, space of the neck
- Children age 6 months to 6 years
- Other deep neck abscesses more frequent in older children & adults
  - Parapharyngeal
  - Peritonsillar
- Potential for airway compromise
- Complications secondary to mass effect, rupture of the abscess, or spread of infection

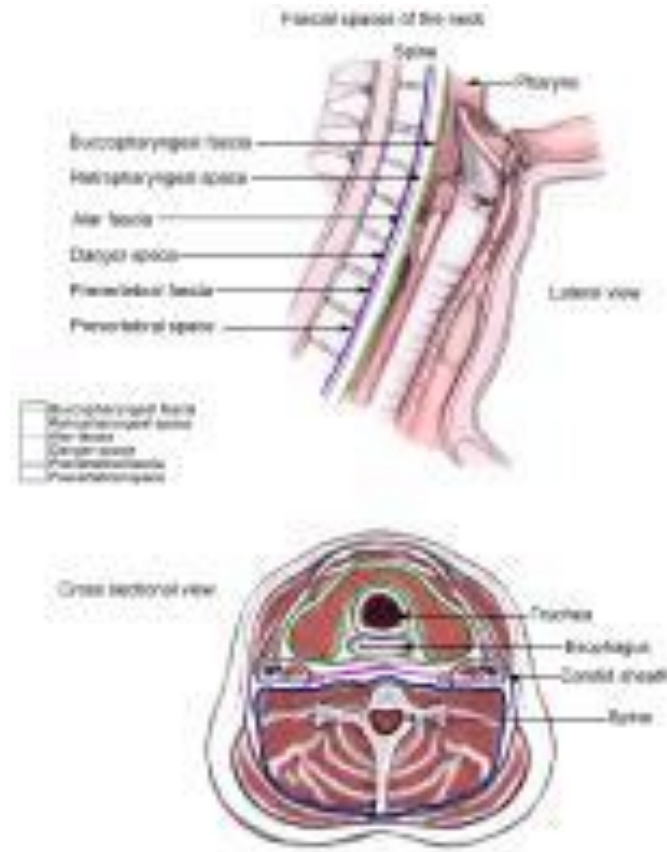
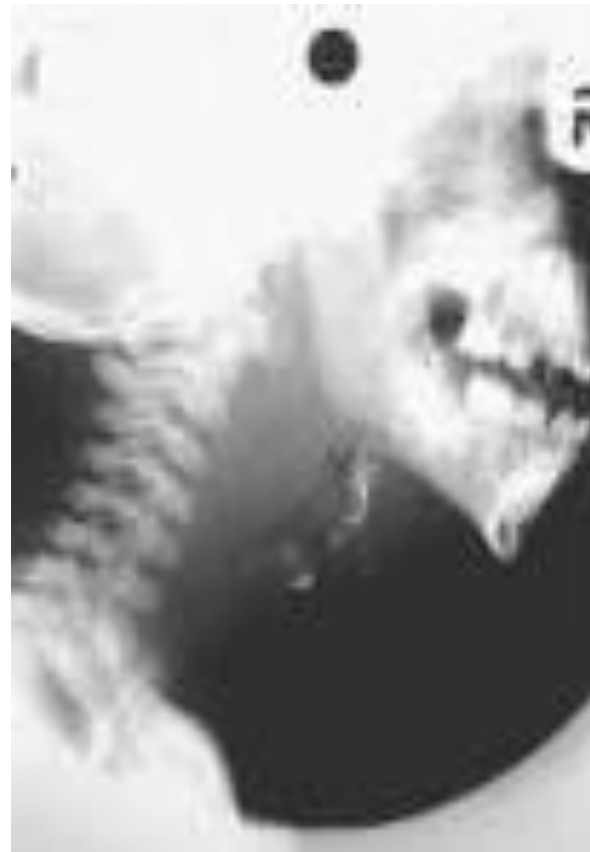

# RETROPHARYNGEAL ABSCESS - SXS

- Fever, chills, malaise
- Decreased appetite
- Irritability
- Sore throat
- Difficulty or pain swallowing
- Jaw stiffness
- Neck stiffness
- Muffled voice
- “Lump” in the throat
- Pain in the back & shoulders upon swallowing
- Difficulty breathing is an **ominous** complaint that signifies impending airway obstruction



# RETROPHARYNGEAL ABSCESS



- 18 mo presents to ED w/ difficulty breathing
- H/O rhinorrhea and fever for 3 days
- Awoke in middle of the night w/ barking cough and noisy breathing
- Symptoms worsen when agitated
- VS: T 102.5, HR 160, RR 40, O2 Sat 95%
- Hoarse cry, Audible stridor, supraclavicular and suprasternal retractions



# CROUP (LARYNGOTRACHEOBRONCHITIS)

- Most severe in kids 6 mo - 3 years old
- Males
- Winter months
- Associated illnesses
  - Ear infection
  - Pneumonia
  - Organisms: parainfluenza types 1, 2 & 3, adenovirus, RSV, influenza



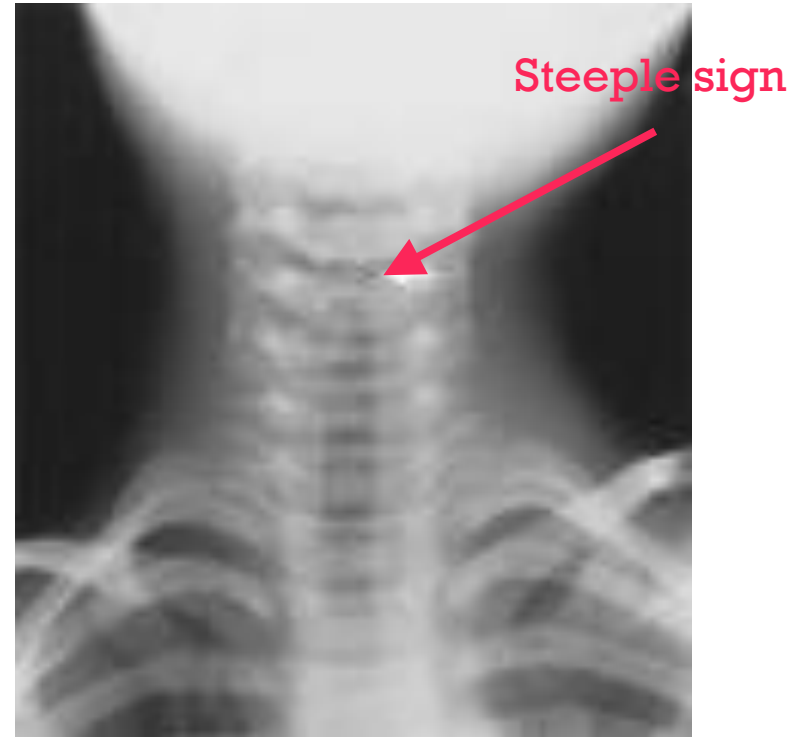# CROUP SYMPTOMS

- URI symptoms X 1-3 days
- Low grade fever
- “Barking” cough, hoarseness
- Inspiratory stridor
- Worse at night
- Prefer to sit up
- Aggravated by agitation & crying



# CROUP DIAGNOSIS

- Clinical diagnosis
- Does not require neck X-ray
  - Consider X-ray in patients with atypical presentation or clinical course
- “Steeple sign”





- Westley croup score most common
- Tool to describe severity of obstruction
- Higher the score, the greater the risk for resp failure

**TABLE 3-5 Clinical Croup Score\***

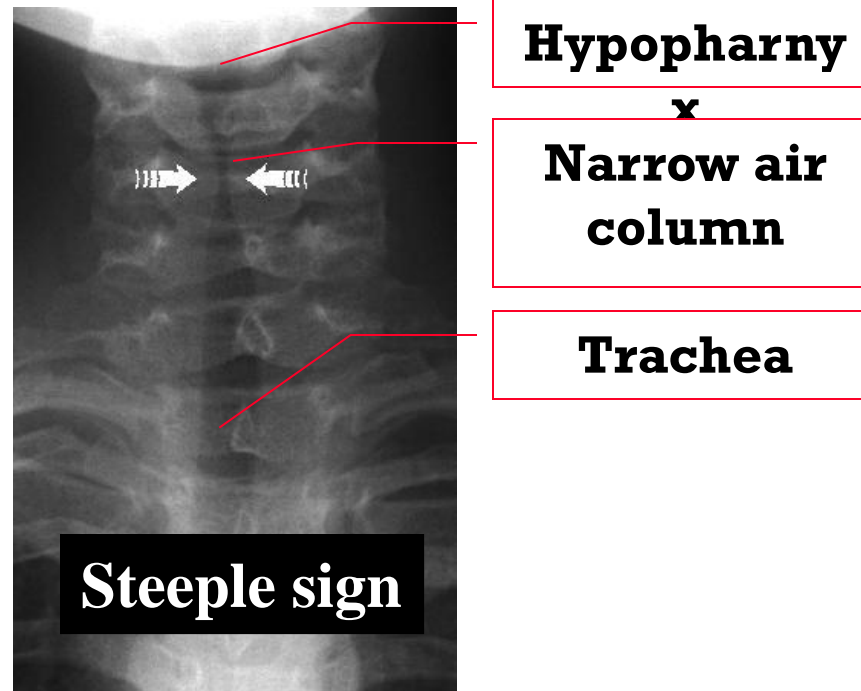
	0	1	2
Cyanosis	None	In room air	In 40% O <sub>2</sub>
Inspiratory breath sounds	Normal	Harsh with rhonchi	Delayed
Stridor	None	Inspiratory	Inspiratory and expiratory or stridor at rest
Cough	None	Hoarse cry	Bark
Retractions and flaring	None	Flaring and suprasternal retractions	Flaring and suprasternal retractions plus subcostal and intercostal retractions

\*A score of  $\geq 4$  indicates moderately severe airway obstruction. A score of  $\geq 7$ , particularly when associated with  $Paco_2$  of  $>45$  and  $PaO_2$  of  $<70$  (in room air), indicates impending respiratory failure.



# CROUP TREATMENT & TRANSPORT

- Position of comfort, with parent
- Dexamethasone 0.6 mg/kg IV/IM
- Epi neb
- Heliox
- SQ Epi
- Cool mist



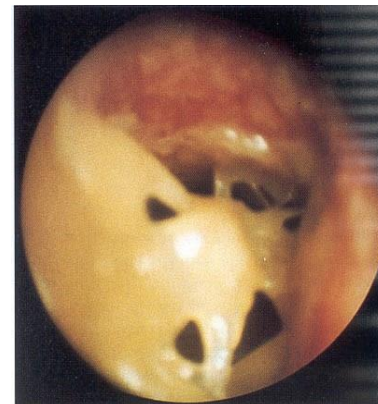
# TRACHEITIS/ PSEUDOMEMBRANOUS CROUP

- Bacterial infection subglottic region
- Same age group as croup
  - Average 3 yrs
- High fevers
- Look toxic
- Mortality 4-20%
- Characterized:
  - subglottic edema
  - inflammation larynx, trachea, bronchi, lungs
  - Copious purulent secretions
- **Polymicrobial:**
  - Staph Aureus ( most likely)
  - S. pneumoniae
  - H. influenzae
- Distress severe, not responsive to croup tx
- Complications- pneumonia, ARDS, Pulm edema, subglottic stenosis



# BACTERIAL TRACHEITIS

- Complication of viral laryngotracheobronchitis
- Fever, white count, respiratory distress following a complicated course of croup
- Staphylococcus aureus- need appropriate antibiotic coverage
- Diagnosis usually made by direct visualization when intubating
- Require aggressive pulmonary toilet/ supportive care
- **Rare- but has emerged as most common potentially life-threatening upper airway infection in children**
- Hopkins, et al, Pediatrics 2006:
  - 3 x as likely to cause resp failure than croup and epiglottitis combined

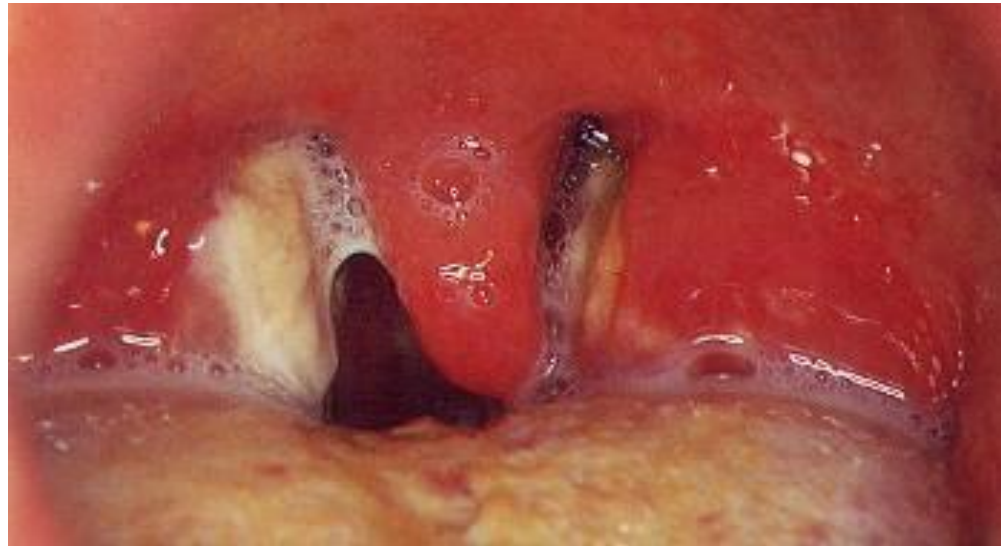

- 12 yr old female
- Fatigue, malaise, fevers 102+ x 3-4 days
- Sore throat, difficulty swallowing
- Pain “ so bad- can’t drink”
- Feels dizzy when standing
- Denies sexual activity
- Mom thinks she “ talks funny”
- Dry, pale, non-toxic appearing
- Foul breath
- Muffled voice
- Large posterior chain nodes, tender to touch
- Neck decreased ROM due to pain
- HR 120’S, orthostatic



# LABS

- Soft belly, ? Spleen tip palpable
- Appropriate, GCS 15
- HCG -, WBC 17, 23% Atypical lymphs on differential, no blasts, platelets 127, lfts minimally elevated



# Infectious mononucleosis

- Caused by Epstein- Barr Virus (EBV)
- Transmitted via contact w/ oropharyngeal secretions
- Incubation period 4-6 weeks
- Typical presentation:
  - Adolescent or young adult
  - Fever
  - Pharyngitis
  - Lymphadenopathy
  - Splenomegaly



# Infectious mononucleosis

- Other constitutional findings: h/a, anorexia, myalgias, chills, rash ( generalized maculopapular), malaise
- Rare complications: myocarditis, myositis, transverse myelitis, encephalitis, pancreatitis/ cholecystitis, glomerulonephritis
- Spontaneous splenic rupture 1-2 %
- Labs supportive of EBV:
  - elevated transaminases; relative lymphocytosis w/ > 10% atypical lymphs; mild leukocytosis (12-20,000); mild thrombocytopenia; elevated ESR or CRP





# KISSING DISEASE

- May cause upper airway obstruction in young children
- Management Supportive:
  - Admit for severe distress
  - Fluids
  - Steroids
  - Pain control
- Get EBV Titers
  - mono spot often false negative in kids < 10 yrs and symptoms < 5 days
- Avoid contact sports for 3-4 weeks
- Close follow up w/ PCP



# Retropharyngeal Abscess

Most common kids: **2-4 yrs**

Symptoms related to pressure and inflammation caused by abscess

Intense dysphagia

Drooling

Respiratory distress- stridor, tachypnea

Usually febrile and fussy

**Unwilling to move neck**

Extension > Flexion

Pt holds neck stiffly

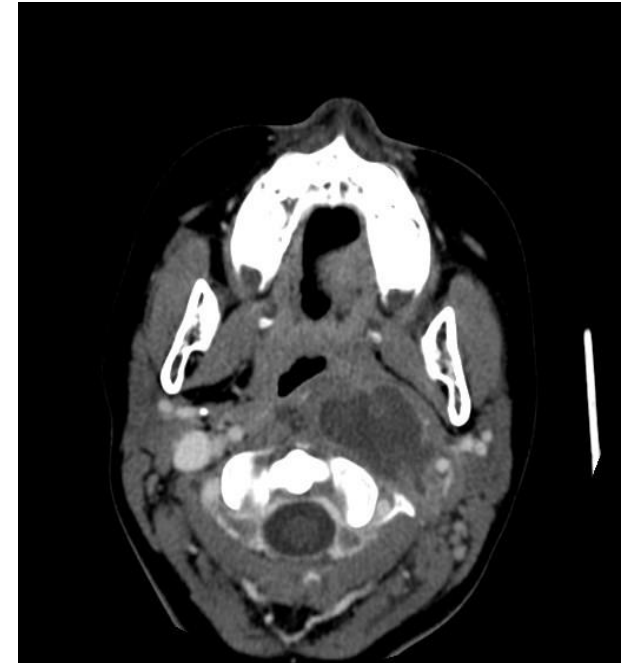
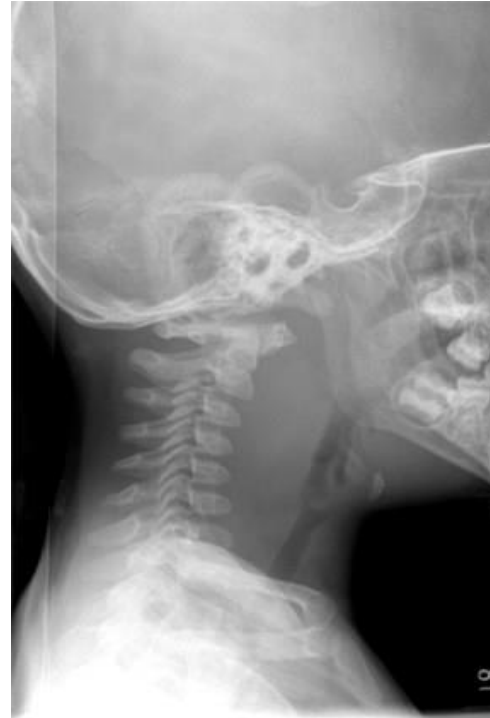**Mimic meningismus**

Group A strep, *S. aureus*, anaerobes

CT will help define abscess

Medical management successful 50%

May require surgical drainage- especially if airway compromise



# RETROPHARYNGEAL ABSCESS

- Polymicrobial infection typical
  - Gram-positive organisms and anaerobes predominating
  - Gram-negative bacteria possible
  - Oropharyngeal flora
- Most common cause is group A beta-hemolytic streptococci



# RETROPHARYNGEAL ABSCESS - RX

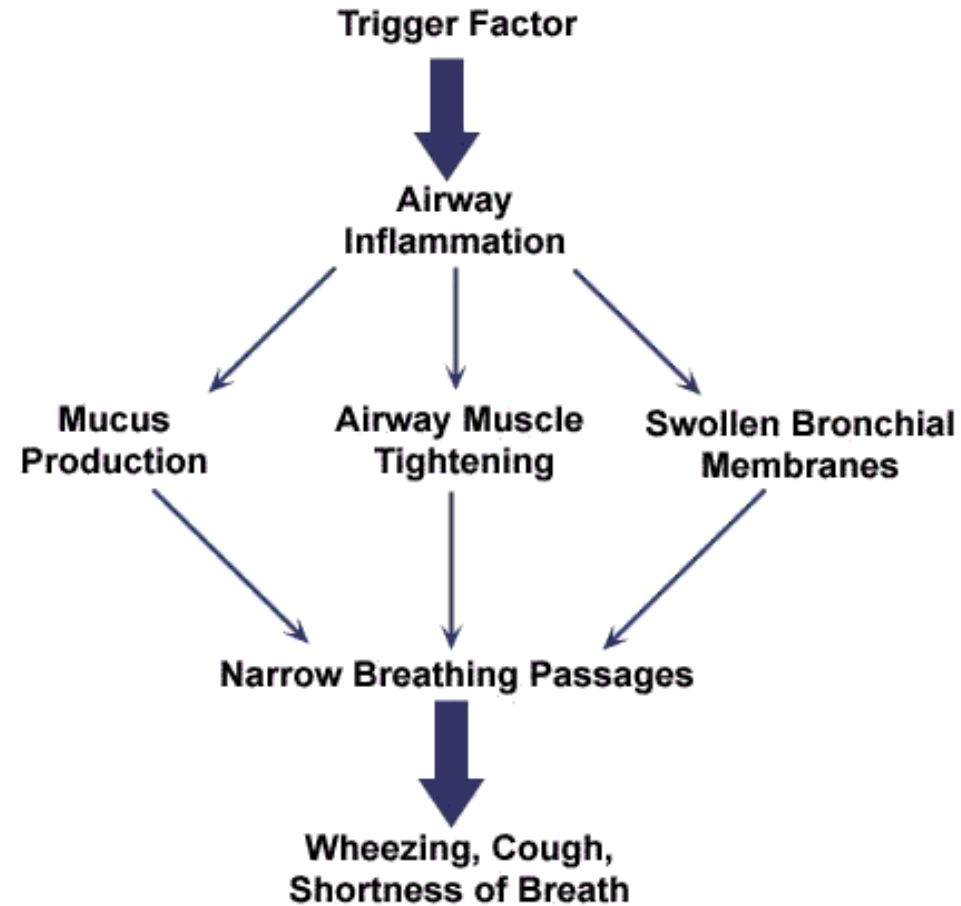
- Position airway - comfort
- Avoid unnecessary manipulation
- Monitor, CT of neck, possible OR
- Sedation & paralytics can relax airway muscles, leading to complete obstruction
- Endotracheal intubation is dangerous
- Abx: clindamycin, cefoxitin, Timentin, Zosyn, or Unasyn



- 12 yr old male
- URI symptoms x 3 days, non-productive cough
- Increased distress past 6 hours
- Long hx asthma; Multiple admissions, PICU x 2, never intubated
- Ran out of Albuterol- used 1 MDI past week ; Flovent “ as needed”, but ran out 1 mth ago
- Mom smokes, but “ not in house”
- Doesn't know what peak flow meter is
- NRB placed, sats up to 95 % on 100% FIO2
- Albuterol started at triage
- Pt still in distress What do you want to do?
- Where will this pt go?
- Does he need blood gas? Will chest film change your management?

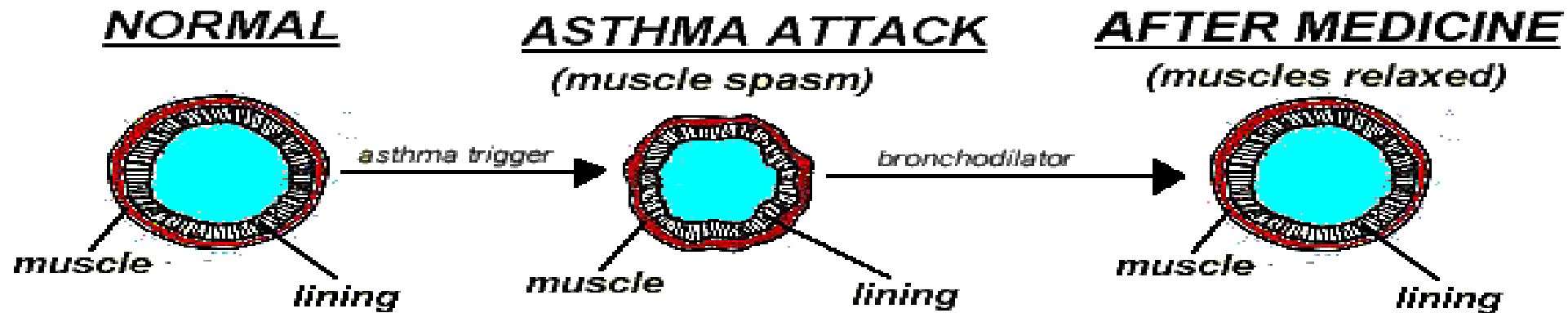


# REACTIVE AIRWAY DISEASE / ASTHMA



# RAD / ASTHMA - CHILDREN

- <3 years - small intrapulmonary airways
- Poor collateral ventilation
- Decreased elastic recoil pressure
- Partially developed diaphragm



# RAD / ASTHMA

- Identify and remove asthma triggers
- Albuterol, nebulized
- Ipratropium bromide (Atrovent)
- Methylprednisolone (Solumedrol)
- Magnesium sulfate
- CPAP / BiPAP
- Heliox
- Epinephrine or terbutaline infusion
- Chest squeeze
- Anesthetic gases

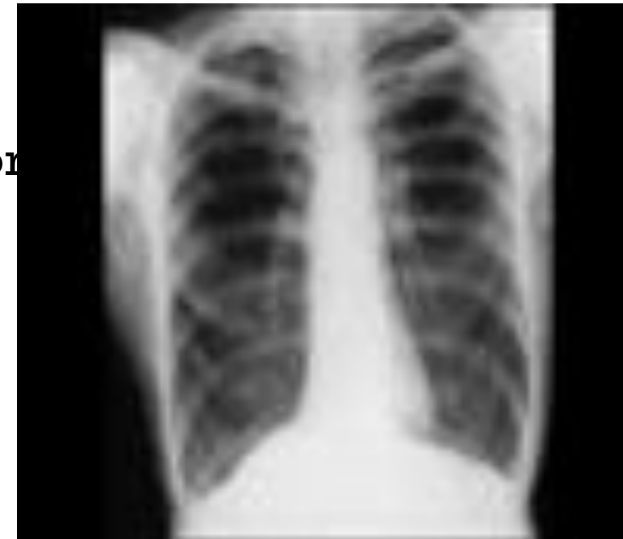



# RAD / ASTHMA

- If intubated for transport:
  - Low vent rate, even if  $p\text{CO}_2$  high
    - Very prolonged expiratory phase
    - Listen to chest - does expiration end?
  - Sedate
  - Paralyze
  - Continuous nebs
  - Monitor for development

of pneumothor



# DIFFERENTIAL DIAGNOSIS FOR A WHEEZING INFANT

- Viral bronchiolitis
- Other pulmonary infections (eg, pneumonia, Mycoplasma, Chlamydia, tuberculosis)
- Laryngotracheomalacia
- Foreign body, esophageal or aspirated
- Gastroesophageal reflux
- Congestive heart failure
- Vascular ring
- Allergic reaction
- Cystic fibrosis
- Mediastinal mass
- Bronchogenic cyst
- Tracheoesophageal fistula



# Treatment

- Inhaled Beta agonists
- Nebulized Anticholinergic Agents
- Corticosteroids
- Magnesium sulfate
- Heliox
- Intubation



# Mechanical Ventilation

- Should be avoided if at all possible
- Should be “last resort”
- Increases airway hyper-responsiveness
- Increased risk barotrauma
- Increased risk circulatory depression/arrest
- Early recognition poor response to therapy/ potential PICU admission
- Indications include severe hypoxia, altered mentation, fatigue, resp or cardiac arrest
- Rising CO<sub>2</sub> in face of distress or fatigue
- Ketamine if intubation required

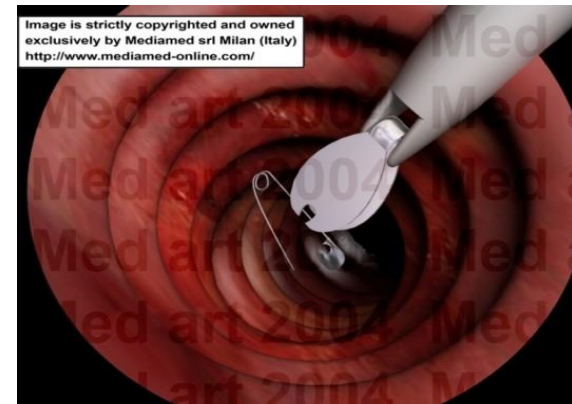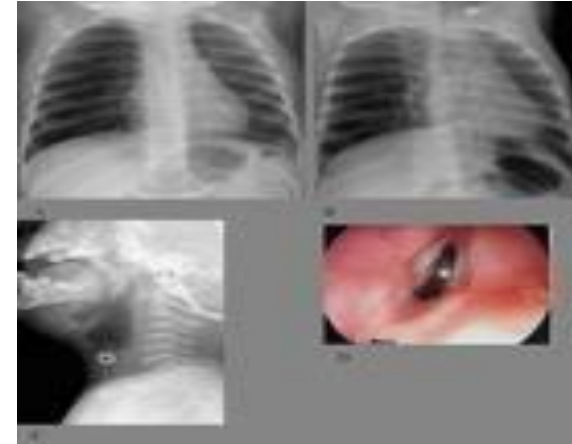


- 18 mo sudden onset of cough and difficulty breathing
- No fever, drooling
- Exam:
  - T 99, P 130, RR 40, O2 Sat 93%
  - Mild intercostal retractions, no stridor, exp wheezing on left side



# Foreign Body Aspiration

- Foreign objects can be lodged in the upper or lower airway, or esophagus.
- Differences in the pediatric airway make evaluation and management of foreign body aspiration challenging.



# FOREIGN BODY (FB) ASPIRATION

- Toddler through preschool age common
  - No molar teeth for thorough chewing
  - Talking, laughing, and running while eating
- In 2000, FB aspiration in kids <14 years old
  - >17,000 ED visits
  - 160 deaths
- Nuts, raisins, sunflower seeds, pieces of meat and small smooth (grapes, hot dogs, & sausages)
- Dried foods absorb water



# FB ASPIRATION

- Sudden episode of coughing / choking while eating with subsequent wheezing (sometimes unilateral), coughing, or stridor
- Tragic cases occur with total or near-total occlusion of the airway
- Frequent sites of FB lodgement:
  - Usually below vocal cords
  - Mainstem bronchi
  - Trachea
  - Lobar bronchi





# FB ASPIRATION

- Extrathoracic FB:
  - Breath sounds are **inspiratory**
- Intrathoracic FB
  - Noises are **symmetric** but more prominent in central airways
  - If FB is beyond the carina, the breath sounds are usually **asymmetric**
    - Kid chest transmits sounds well
    - Stethoscope head may be bigger than lung lobes
    - Lack of asymmetry should not dissuade you from considering the FB diagnosis

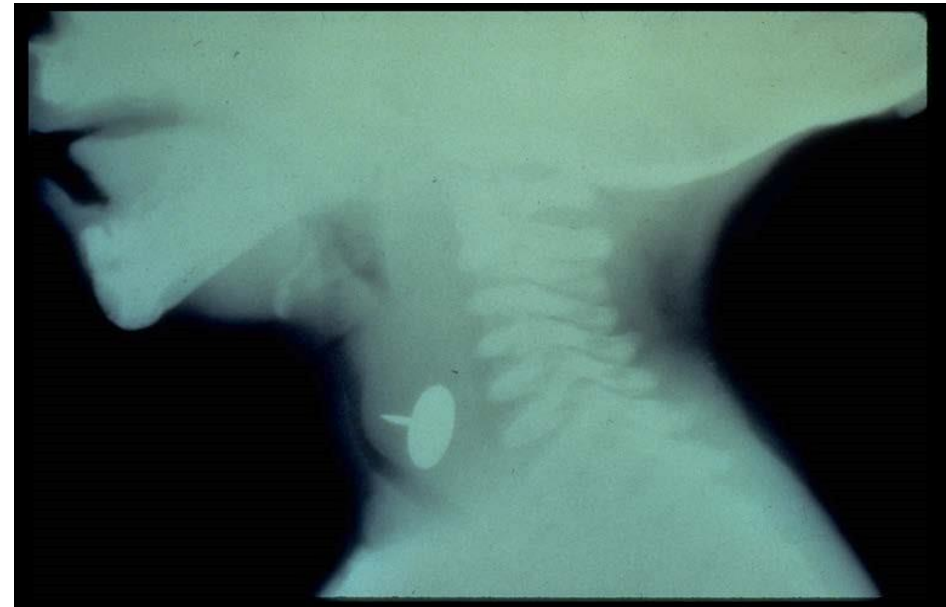
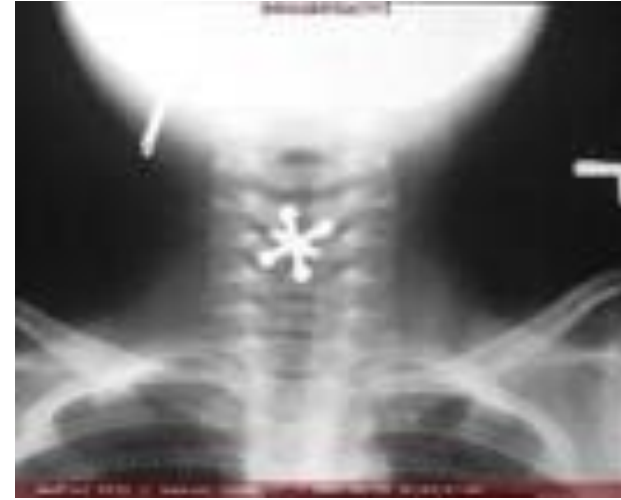

# FB ASPIRATION

- Hyperinflation & air-trapping of the affected lobe(s) is typical
  - Best seen with X-ray taken at expiration
  - Difficult in little kids
- May see soft tissue opacity in proximal airway

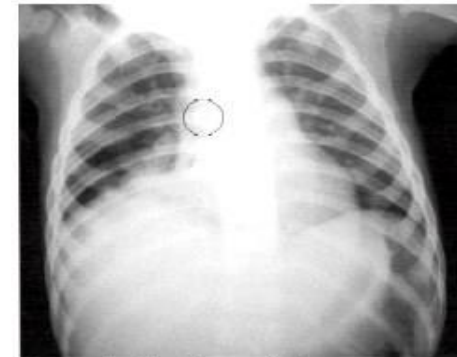


- Seen in children <5 years old
- Symptoms variable; may be acute, subacute, or chronic
- Upper or lower airway symptoms
- Maintain a high degree of suspicion
- Radiography useful for incomplete obstruction

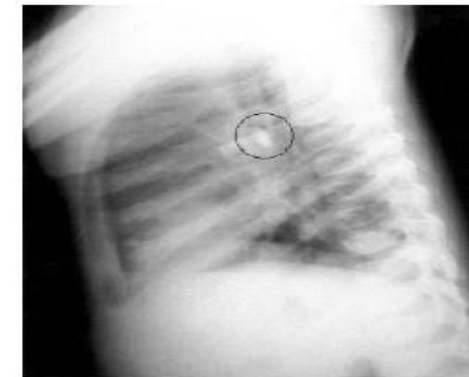


# Aspirated Foreign Bodies

- Identification can be quite subtle
- FB aspiration relatively uncommon event
- Initial choking episode may be unwitnessed
- Delayed residual symptoms mimic other common conditions like asthma, URI, pneumonia
- Initial diagnosis missed in 30% of patients
- High index of suspicion required
- **“All that wheezes is not asthma”**



Case 1 A – First X-ray which was interpreted as pneumonia; circle shows the foreign body in the right main bronchus.



Case 1 B – Lateral view; circle shows the foreign body.

# FOREIGN BODIES

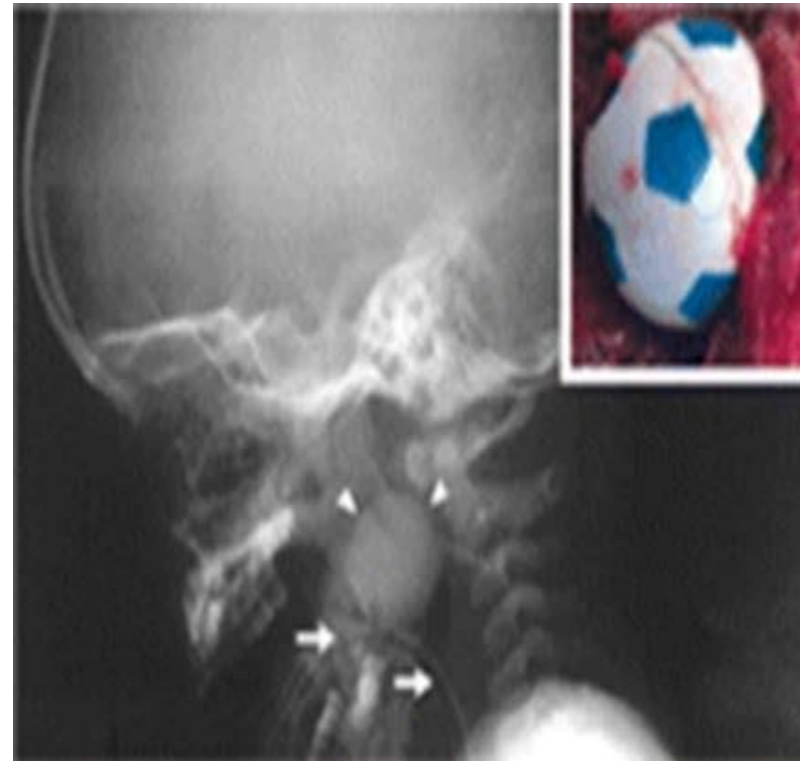
- 2-4year olds
- Acute episode of choking/gagging
- Triad of acute wheeze, cough and unilateral diminished sounds only in 50%
- 5-40% of patients manifest no obvious signs
- Think FB if persistent symptoms despite appropriate therapy
- Think FB if acute onset cough, gagging
- **Any child eating, running and acute onset distress = FOREIGN BODY**





# FB Aspiration Symptoms

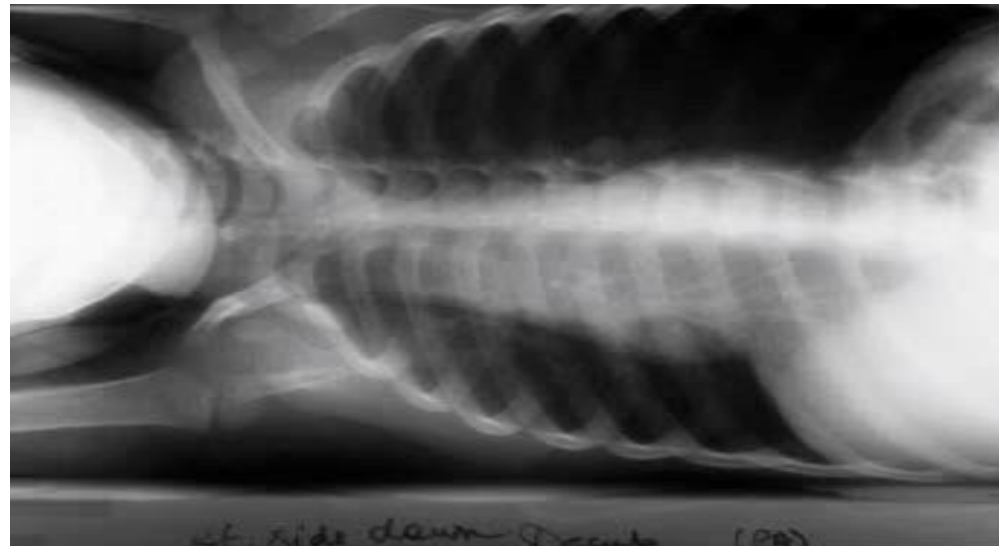
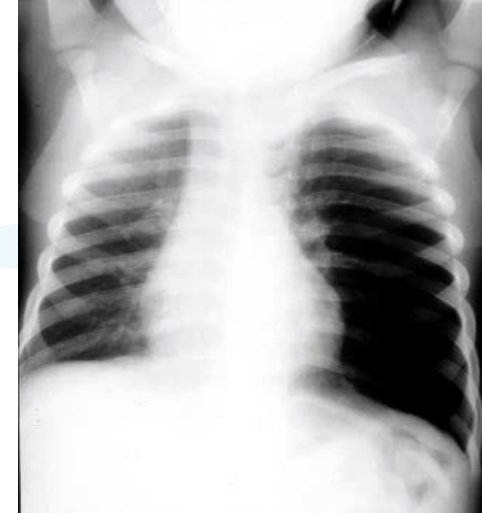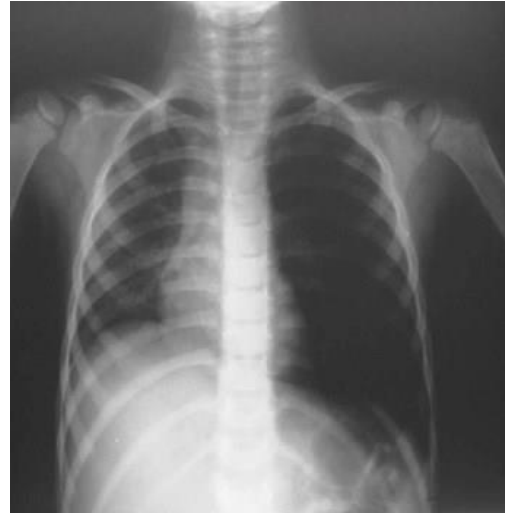- Choking (22-86%)
- **Coughing (22-77%)**
- Dyspnea/ SOB (4-49%)
- Fever (12-37%)
- Wheezing (22-40%)
- **Stridor (1-61%)**
- Hemoptysis (1-11%)
- Asymptomatic (1-6%)



# Radiologic Diagnosis

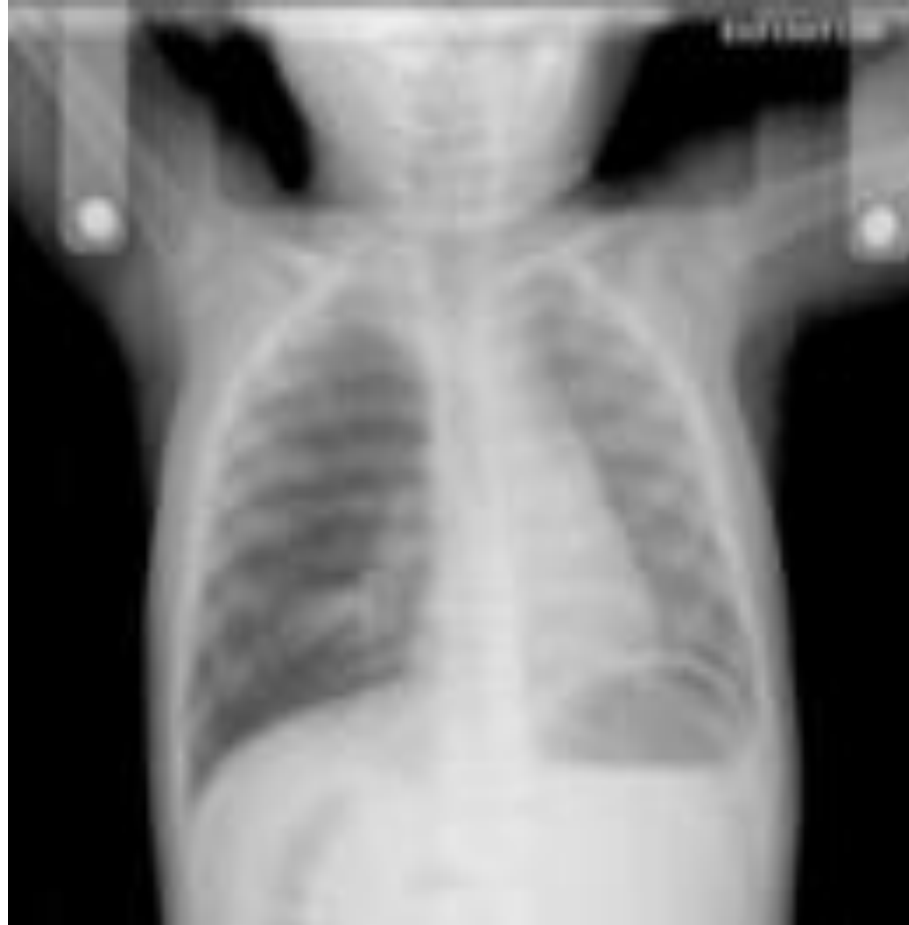- **Xrays can not rule out non-radiopaque FB aspiration**
- Majority aspirated FB radiolucent
- AP, lateral chest films- normal 25% aspirated FB
- Inspiratory/Expiratory films require patient cooperation
- Decubitus views- “poor man’s” expiratory film
- Down side is expiratory
- **Most common findings :**

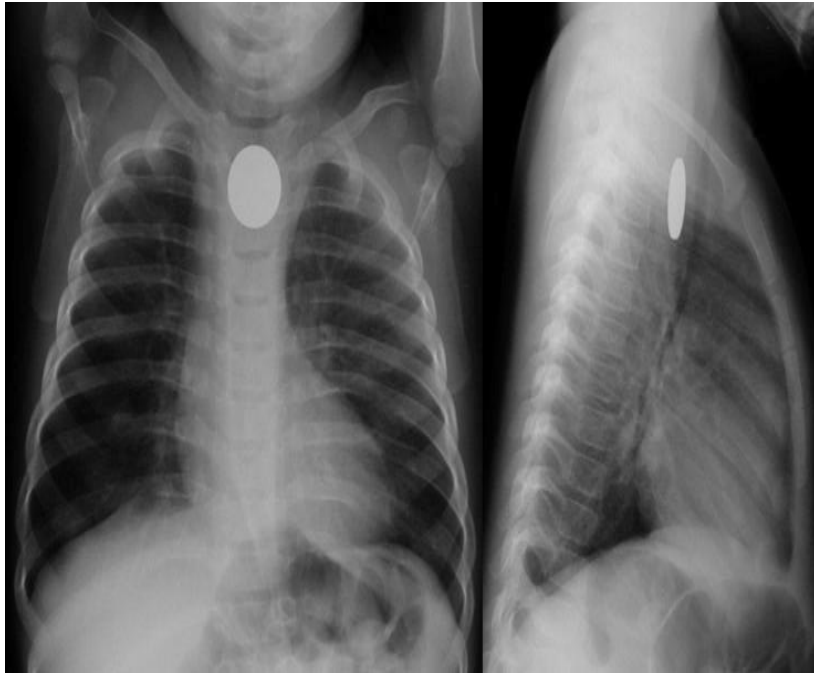
hyperinflation/air trapping  
atelectasis  
pneumonia



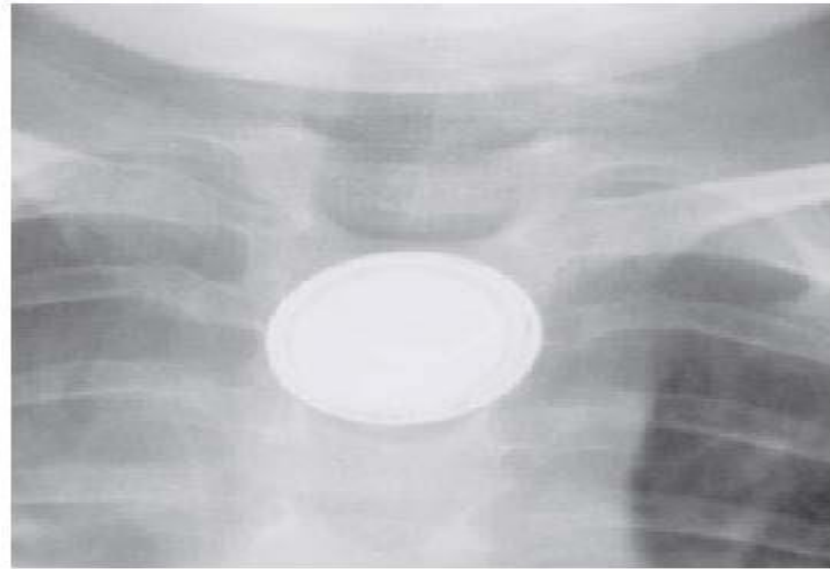


# FB ASPIRATION






**Figure 7. Button batteries have a distinctive appearance on radiographs.**



**Figure 7b. Lateral comparison of coin and button battery.**

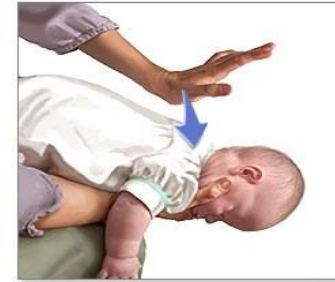

**Figure 7a. Frontal comparison of coin and button battery.**

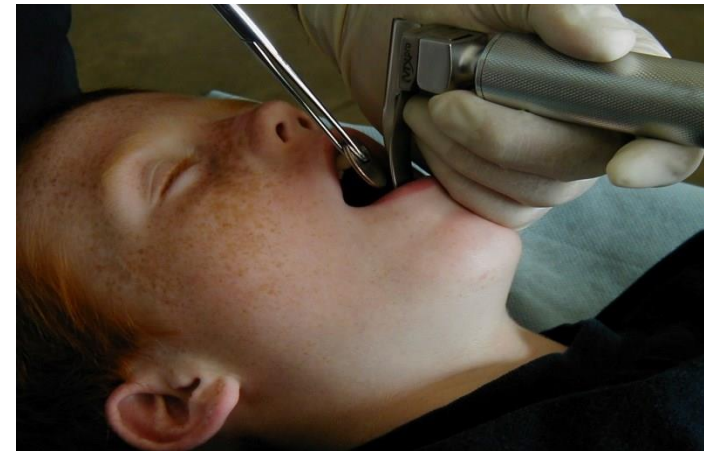
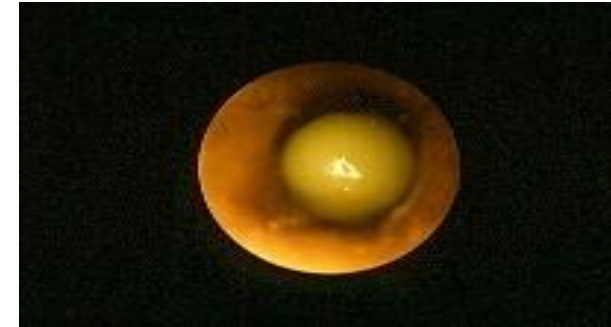

- Bronchoscopy- diagnostic/therapeutic treatment of choice
- Typically performed by Peds surgery, ENT, pulmonologist
- Unsuccessful bronchoscopy requires need for thoracotomy to remove FB
- Position of comfort
- Reduce agitation
- NPO
- **Be prepared if partial obstruction progresses to complete airway obstruction**
  - heimlich, back blows, Magill forceps, jet ventilation

Place the infant stomach-down across your forearm and give five quick, forceful blows on the infant's back with heel of your hand



ADAM.



# FB ASPIRATION - TRANSPORT ISSUES

- Position of comfort
- Heimlich maneuver, back blows
- BVM prn
- Magill forceps (if object above cords)
- Intubation prn
- Needle cricothyrotomy
- Surgical cricothyrotomy
- Rigid bronchoscopy for FB removal

